

# Is Olmesartan-Induced Angioedema Triggered by Angiotensin Converting Enzyme Inhibition and Kinin Peptides? A Rare Case

## *Olmesartana Bağlı Anjiyoödem, Anjiyotensin Dönüştürücü Enzim İnhibisyonu ve Kinin Peptidazlar Tarafından Tetiklenir mi? Nadir Bir Olgu*

### ABSTRACT

Olmesartan medoxomil (OM) is an angiotensin II receptor blocker (ARB) and it is used for the treatment of hypertension. Among all ARB drugs, only OM shows an angiotensin converting enzyme inhibitory effect (ACEI). OM may cause angioedema by its ARB effect. It can exhibit this role by the endogenous ACEI effect. While the frequency of angioedema associated with ACEI ranges from 0.1% to 1%, the frequency of ARB-induced angioedema is reported to range from 0.1% to 0.4%. A 38-year-old woman was diagnosed with primary hypertension and 20 mg/day OM was started for the management of hypertension. Following the second day of OM treatment, she was admitted to the emergency department because of a new episode of acute angioedema of the tongue, face and lips. OM induced angioedema was diagnosed. OM therapy was switched to a calcium channel blocker.

**KEY WORDS:** Olmesartan, Angioedema, Angiotensin-converting enzyme inhibitors

### ÖZ

Olmesartan medoxomil (OM), anjiyotensin II reseptör blokeridir (ARB) ve hipertansiyon tedavisi için kullanılır. Tüm ARB'ler arasında sadece OM'nin anjiyotensin dönüştürücü enzim inhibitörü (ADEİ) etkisi vardır. OM, ARB etkisi ile anjiyoödem neden olur. Bu rolü endojen ADEİ etkisi sayesinde yapar. ADEİ alımından sonra anjiyoödem sıklığı %0,1 ile %1-5 arasında bulunmasına rağmen, ARB'lerin neden olduğu anjiyoödem %0,1 ile %0,4-6 arasında olduğu bildirilmektedir. 38 yaşında kadın hastaya primer hipertansiyon teşhisi kondu. Hipertansiyon tedavisi için 20 mg/gün OM tedavisi planlandı. Hasta, OM'nin ikinci gününde dudak, yüz ve dilde meydana gelen akut anjiyoödem nedeniyle hastanemiz acil servise başvurdu. OM'nin neden olduğu anjiyoödem teşhisi kondu ve bu nedenle OM tedavisi kalsiyum kanal blokeri ile değiştirildi.

**ANAHTAR SÖZCÜKLER:** Olmesartan, Anjiyoödem, Anjiyotensin dönüştürücü enzim inhibitörleri

### INTRODUCTION

Angiotensin-converting enzyme inhibitors (ACEIs) and angiotensin II type 1 (AT1) receptor antagonists (angiotensin receptor blockers [ARBs]) are used for renin-angiotensin system blockade and prevent cardiovascular events. Dry cough, angioedema, hypotension, hyperkalemia, or renal dysfunction may appear in approximately 5–20% of patients treated with an ACEI. In ACEI-intolerant patients, ARBs can be prescribed to maintain renin-angiotensin system blockade and decrease cardiovascular risk. Although meta-analysis

studies suggest that patients treated with ARBs have an angioedema risk similar to those taking placebo, angioedema has appeared increasingly in patients taking ARBs. OM is a relatively new member of ARBs. We present here a case of rapid onset angioedema at the second day of OM treatment.

### CASE REPORT

A 38-year-old woman was diagnosed with primary hypertension and 20 mg/day OM was started for management of hypertension. She had suffered from

**Kenan TURGUTALP<sup>1</sup>**

**Ebru Zeynep ESER<sup>1</sup>**

**Tolga KÖŞECİ<sup>1</sup>**

**Türkay ÖZCAN<sup>2</sup>**

**Sezer ÇİÇEKLİ TURGUTALP<sup>3</sup>**

**Yavuz GÖZÜKARA<sup>4</sup>**

**Ahmet ÇAMSARI<sup>2</sup>**

**Ahmet KIYKIM<sup>1</sup>**

- 1 Mersin University Faculty of Medicine, Department of Internal Medicine, Division of Nephrology, Mersin, Turkey
- 2 Mersin University Faculty of Medicine, Department of Cardiology, Mersin, Turkey
- 3 Mersin State Hospital, Department of Dermatology, Mersin, Turkey
- 4 Mersin State Hospital, Department of Internal Medicine, Mersin, Turkey



Received : 18.06.2013

Accepted : 21.10.2013

Correspondence Address:

**Kenan TURGUTALP**

Mersin Üniversitesi Tıp Fakültesi,

İç Hastalıkları Anabilim Dalı,

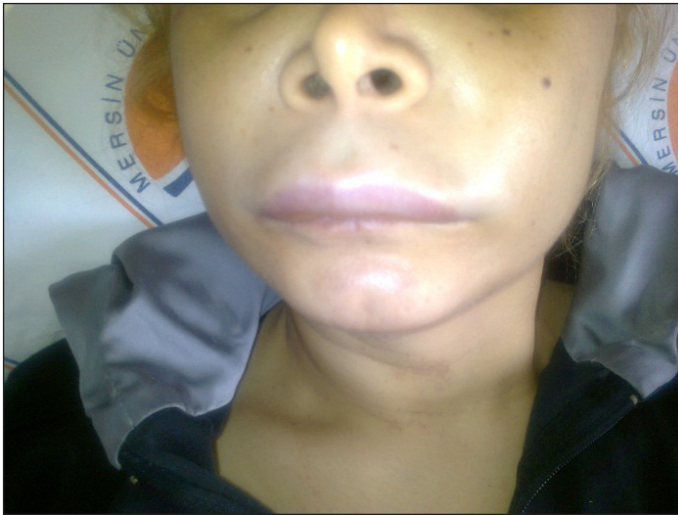Nefroloji Bilim Dalı, Mersin Turkey

Phone : + 90 532 492 68 83

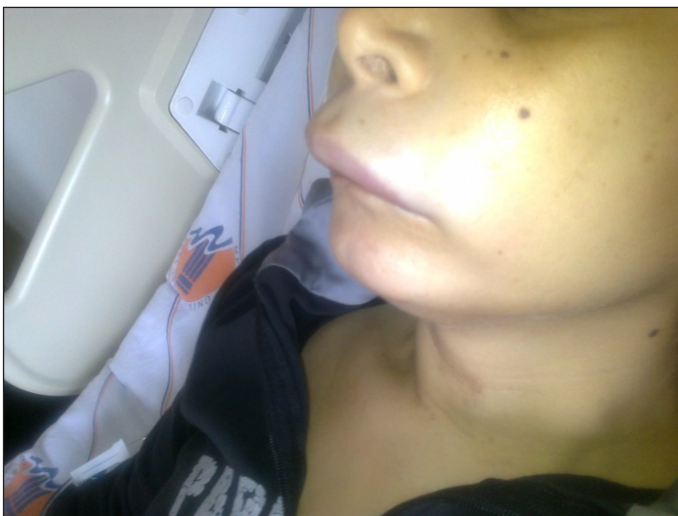
E-mail : k.turgutalp@hotmail.com

rheumatoid arthritis for 16 years, and had been treated with leflunomide 10 mg/day for 2 years. On the second day of OM treatment, she was admitted to the emergency service because of immediate swelling in the tongue, left side of her face and upper lip, and dyspnea. She had no previous history of these complaints or trauma, and they did not appear to be associated with meals or drugs. She did not report a personal or family history of asthma or any allergic condition, and smoked about 10 cigarettes per day.

On admission, blood pressure was 140/90 mmHg, the respiratory rate was 28/min., the pulse rate was 94/min, and the body temperature was 36.5 °C. She had a diffuse, soft, and nontender mild swelling of the left tongue and floor of mouth, and severe swelling on her left face and upper lip (Figure 1, 2).



**Figure 1:** Angioedema of her upper lip and left side of the face.



**Figure 2:** Angioedema of her upper lip and left side of the face lateral view.

Cervical lymphadenopathy was not detected. The patient was afebrile and had no laryngeal edema. The other findings of the examination were normal. Laboratory findings on admission were as follows: hemoglobin 10.5 gr/dl; white blood cell count 11.600/mm<sup>3</sup>; erythrocyte sedimentation rate 25 mm/h; C-reactive protein level 12 mg/l (normal range, 0-5); Rheumatoid factor 28 IU/ml (normal <10 IU/ml). Anti-nuclear antibody, anti-ds-DNA antibody, and complement levels were found to be normal. Liver enzymes, serum creatinine, and urinalysis were also normal. C<sub>1</sub> esterase inhibitor deficiency was not found. Chest-x-ray and skull x-ray examination was also normal. All other laboratory findings were within the normal range.

OM-induced angioedema was diagnosed and OM treatment was stopped. The patient was treated with corticosteroids and antihistamines. After the treatment and discontinuation of OM, the abnormal physical findings disappeared and the patient improved. Follow-up at 3, 6 and 12 months after discharge revealed no recurrence of angioedema.

## DISCUSSION

Angioedema is a localized, transient, serious and sometimes life-threatening adverse event that usually manifests as swelling of the lips, tongue, mouth, larynx, gastrointestinal system, hands or periorbital region. It has been linked to the use of some medications, particularly ACEIs. Patients with a previous history of idiopathic angioedema or C<sub>1</sub> esterase inhibitor deficiency are at increased risk of developing angioedema during treatment with ACEIs (1). The etiology is not completely understood. There is limited evidence for ACEI-induced angioedema that may be triggered by increasing the level of bradykinin (2). Furthermore, it has been suggested that there may be an abnormality of degradation of the active metabolite of bradykinin, des-Arg9-BK, in patients with ACEI-induced angioedema (3). While the frequency of angioedema associated with ACEI ranges from 0.1% to 1%, the frequency of ARB-induced angioedema is reported to range from 0.1% to 0.4%, similar to placebo (4).

ARB-induced angioedema has developed with various ARBs including losartan, valsartan, candesartan, irbesartan, telmisartan, and eprosartan. In the literature, and two case reports of olmesartan induced-angioedema are present (5). The frequency of angioedema relapse in patients who formerly experienced ACE-inhibitors-induced angioedema and had received ARBs has varied from very low to 50% (4). Clinical characteristics of angioedema due to either ACEIs or ARBs are similar. These features suggest that there may be a common pathogenetic mechanism in the development of ACEI-induced angioedema and ARB-related angioedema. Our patient had never been treated with ACEIs previously.

It is usually believed that ACEIs accelerate angioedema by directly influencing the degradation of bradykinin and potentiating its biological action. Several types of ARBs including losartan have been shown to increase both plasma

renin activity and plasma angiotensin II (Ang II) concentrations in hypertensive patients (6). In humans, Campbell et al. demonstrated that losartan increases bradykinin levels by decreasing its metabolism (7). The authors concluded that this finding is a class effect of AT1 receptor blockers. Furthermore, they suggested that bradykinin could also contribute to the angioedema that may accompany losartan therapy. In contrast, Ichikawa et al. reported that long-term treatment with OM results in a reduction of the plasma Ang II level (8). In a recent study, Agata et al. showed that OM has an endogenous ACEI effect through an increase in angiotensin 1-7 (Ang-(1-7)) via over-expression of ACE2 (9). OM increases ACE2 expression in the remodeling heart after myocardial infarction, which theoretically could contribute to the beneficial effects of ARBs by facilitating increased cardiac Ang-(1-7) formation (10). It has also been reported that Ang-(1-7) inhibits the ACE C-domain and potentiates bradykinin by acting as an ACEI. We believe that OM-induced angioedema is triggered by angiotensin converting enzyme-inhibition and kinin peptides

### CONCLUSION

ACEI and consequently the kinin peptides may have role in development of angioedema. Some previous cases of angioedema due to ACEI and ARBs with similar clinical findings have been reported. OM-related angioedema should therefore be considered hypertension patients on medical treatment.

### REFERENCES

1. Zuraw BL, Christiansen SC: Pathophysiology of hereditary angioedema. *Am J Rhinol Allergy* 2011;25:373-378
2. Bas M, Hoffmann TK, Kojda G, Bier H: ACE-inhibitor induced angioedema. *Laryngorhinootologie* 2007;86:804-808
3. Molinaro G, Cugno M, Perez M, Lepage Y, Gervais N, Agostoni A, Adam A: Angiotensin-converting enzyme inhibitor-associated angioedema is characterized by a slower degradation of des-arginine(9)-bradykinin. *J Pharmacol Exp Ther* 2002;303:232-237
4. Caldeira D, David C, Sampaio C: Tolerability of angiotensin-receptor blockers in patients with intolerance to angiotensin-converting enzyme inhibitors: A systematic review and meta-analysis. *Am J Cardiovasc Drugs* 2012;12:263-277
5. Vasquez JL, Jaramillo JC, Fernandez C, Enriquez A, Mielgo R: Severe angioedema associated with olmesartan. *Ann Allergy Asthma Immunol* 2011;107:285
6. Bouer IH, Reams GP, Wu Z, Lau-Sieckman A: Effects of losartan on the renin-angiotensin-aldosterone axis in essential hypertension. *J Hum Hypertens* 1995;9: 237-243
7. Campbell DJ, Krum H, Esler MD: Losartan increases bradykinin levels in hypertensive humans. *Circulation* 2005;111:315-320
8. Ichikawa S, Takayama Y: Long-term effects of olmesartan, an Ang II receptor antagonist, on blood pressure and the renin-angiotensin-aldosterone system in hypertensive patients. *Hypertens Res* 2001;24:641-646
9. Agata J, Ura N, Yoshida H, Shinshi Y, Sasaki H, Hyakkoku M, Taniguchi S, Shimamoto K: Olmesartan is an angiotensin II receptor blocker with an inhibitory effect on angiotensin-converting enzyme. *Hypertens Res* 2006;29:865-874
10. Ishiyama Y, Gallagher PE, Averill DB, Tallant EA, Brosnihan KB, Ferrario CM: Upregulation of angiotensin-converting enzyme 2 after myocardial infarction by blockade of angiotensin II receptors. *Hypertension* 2004;43: 970-976