

Mucoepidermoid Carcinoma in Warthin Tumor of the Parotis in Childhood: A Case Report and Review of the Literature

Elvan Caglar Citak, MD,* Eda Bengi Yılmaz, MD,† Fatih Sagcan, MD,*
Funda Bozkurt, MD,‡ Rabia Bozdogan Arpacı, MD,‡ and Yusuf Vayisoglu, MD§

Summary: Mucoepidermoid carcinoma arising in Warthin tumor of the parotid gland is an extremely rare entity. This is so far described only in the adult age group, and only one patient has been reported in the pediatric age group until today. Herein, we describe our patient and review the literature. This was a case of a 9-year-old girl admitted with a painless swelling in the left side of her face for at least 2 weeks. Histopathologic examination of total parotidectomy specimens revealed mucoepidermoid carcinoma arising in the Warthin tumor. This case is the youngest patient reported to date.

Key Words: mucoepidermoid carcinoma, Warthin tumor, childhood
(*J Pediatr Hematol Oncol* 2019;41:494–497)

Salivary gland tumors are rare in children and adolescents and constitute only 0.5% of pediatric malignancies. Compared with their adult counterpart, they have a higher tendency to be malignant. Approximately 15% to 25% of salivary gland tumors in adults are malignant, but this is ~25% to 50% in childhood.¹ The parotid gland is the most commonly affected salivary gland affected by carcinoma in childhood. Mucoepidermoid carcinoma is the most frequent histologic type. Other common histologic types are acinar cell carcinoma, cystic adenoid carcinoma, and, less frequently, sialoblastoma.¹

Warthin tumor (WT) among benign tumors is the second most common tumor after pleomorphic adenomas. It affects mainly male individuals, with age of onset at 60 to 70 years.² However, very rare pediatric cases with WT have been reported. WT is a slow growing, movable, painless soft tissue mass usually located in the superficial lobe of the parotid gland that can be revealed by ultrasonography (USG) as a well-defined hypoechoic mass. A variable mixture of lymphoid stroma and double-layered oncocytic columnar epithelium characterizes WT. Malignant transformation and carcinoma arising in WT is extremely rare. Malignant transformation is more common in the lymphoid component than in the epithelial component. Squamous cell carcinoma, mucoepidermoid carcinoma, oncocytic carcinoma, adenocarcinoma, and undifferentiated carcinoma have been reported as carcinomatous components.³ To our knowledge, there are very few patients with mucoepidermoid carcinomas in the WT of the parotis up to now, and, except for 1 case, they are all in adults.

In this report, we present a 9-year-old girl with mucoepidermoid carcinomas in the WT of parotis and review the literature, and this is the youngest case report as far as we know.

CASE REPORT

A 9-year-old girl admitted to her physician with a painless swelling in the left side of her face for at least 2 weeks. There was no family history of benign and malignant tumor. At that time, physical examination showed lymphadenopathy in the left upper cervical and postauricular region, with the largest one ~3×3 cm in size. She referred to the department of otorhinolaryngology. USG revealed a hypoechoic cystic mass with a thick wall and 2.71.5 cm in size in the left parotid gland. Cervical USG also showed bilateral cervical multiple lymph nodes; the largest was 2×0.9 cm in size and with a cortical thickness along level II. The largest cervical lymph node was excised, and it was reported as reactive hyperplasia. Without any further radiologic investigation, total parotidectomy with preservation of the facial nerve was performed. There was a lesion with a heterogeneous appearance of 2.4×2.3×2.3 cm in size and a cream-white color with cystic areas in the specimen. Hematoxylin and eosin-stained slides showed a cystic tumor with stratified oncocytic epithelium in the lymphoid stroma (Fig. 1A). This area was suggested as benign WT. In focal areas, the lining epithelium, which included oncocytic cells, showed mucin-containing goblet cells along with squamous cells. Some of these cells were of benign character, but some of them showed a transition zone from oncocytic cells to hyperplastic goblet cells, intermediate cells, and atypical squamous cells (Fig. 1B). The stroma underneath the cystic epithelium showed a dense lymphocytic infiltrate forming lymphoid follicles with germinal center, and desmoplastic stroma containing the malignant grandular structures and solid tumor cells near the normal parotis. The extracellular mucin pools, mucinous glands, and squamous cell islands invading into the stroma were also seen (Fig. 1C). The squamous cell islands, which contained atypical nuclear features, were invading the stroma, and the stroma was desmoplastic in character (Fig. 1D). The mucoepidermoid component of the tumor included evident cystic areas, although it was not seen in any perineural invasion, vascular invasion, and anaplasia. As a result of this pathologic evaluation, the patient was diagnosed as having low-grade mucoepidermoid carcinoma in the WT of the parotis. CRTC 1/3-MAML2 fusion genes have not been studied due to technical deficiencies in our case. She was referred to the radiation oncology, but, because of the favorable pathologic findings, she did not receive radiotherapy. She is followed-up with no evidence of recurrent disease 10 months after surgery.

DISCUSSION

WT is the second most common benign tumor of the salivary glands. It is frequently seen in adult male individuals during the sixth and seventh decades of life.² Bilateralism is described in 5% to 15% and multifocality in 6% to 20% of WTs.

Histologically, WT is a well-defined entity with dual component, oncocytic epithelium and lymphoid stroma. Malignant transformation is more common in the lymphoid

Received for publication February 13, 2018; accepted July 25, 2018.
From the Departments of *Pediatric Oncology; †Radiation Oncology;
‡Pathology; and §Otorhinolaryngology, Mersin University, Faculty
of Medicine, Mersin, Turkey.
The authors declare no conflict of interest.
Reprints: Elvan Caglar Citak, MD, Department of Pediatric Oncology,
Mersin University, Faculty of Medicine, Mersin, 33343 Turkey
(e-mail: caglarcitak@yahoo.com).
Copyright © 2018 Wolters Kluwer Health, Inc. All rights reserved.

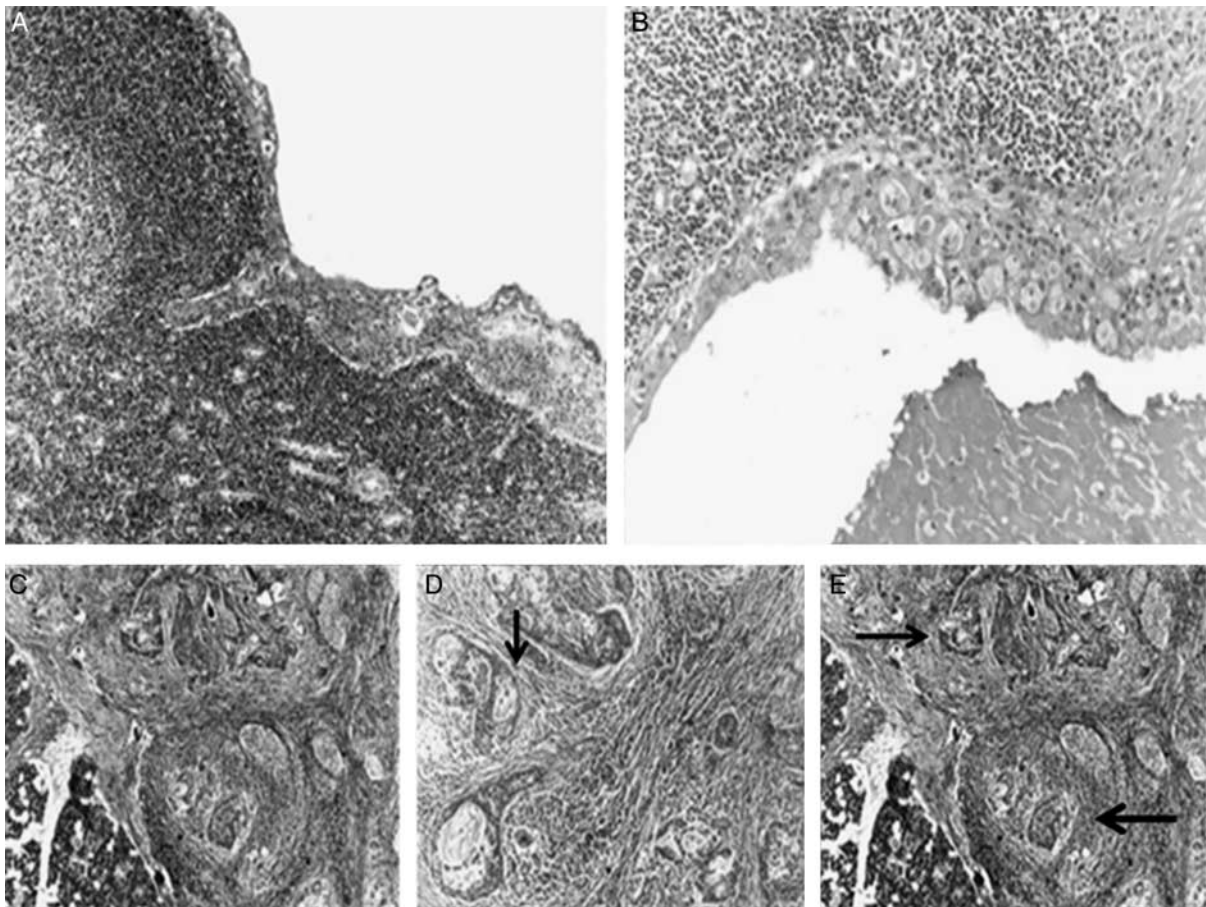


FIGURE 1. A, Warthin tumor-containing oncocytic, mucinous, and squamoid cells with the lymphoid stroma (H-E, ×100). B, The transitional zone, including from oncocytic epithelial cells to squamous and goblet cells, with stratification (H-E, ×200). C, The stroma of the infiltrative area showed a dense lymphocytic infiltrate forming lymphoid follicles with germinal center and desmoplastic stroma containing the malignant glandular structures and solid tumor islands near the normal parotis (H-E, ×100). D, The irregular glands containing intraluminal mucin (black arrow) (H-E, ×200). E, Atypical squamous cell islands with atypical nuclear features (black arrow) were invading the desmoplastic stroma (H-E, ×100). H-E indicates hematoxylin and eosin.

component of WT than in the epithelial component, although malignant carcinoma is very rare and occurs in 0.3% of cases.²

Mucoepidermoid carcinoma commonly occurs in the salivary glands, but is also observed in other organs, including the breast, pancreas, thyroid gland, trachea, and bronchus. Mucoepidermoid carcinoma of the trachea and bronchi is rare, accounting for 0.1% to 0.5% of all lung carcinomas.⁴ Mucoepidermoid carcinoma is one of the most common childhood primary malignant tumors, representing ~10% of malignant lung tumors in children.⁴ Mucoepidermoid carcinoma in WT of the parotid gland seems to be a rare entity, and, so far, only 27 cases have been reported worldwide.^{2,3,5-17}

The youngest and the oldest patients with mucoepidermoid carcinoma in WT of the parotid gland reported were 17 and 74 years old, respectively. To our knowledge, our case is the youngest (9-y old) one in childhood by this time. As previous studies have examined, we found that 1 case had bilateral involvement, and the ratio between right and left parotid gland involvement is almost 1:1, including in our case. Most of the cases had a painless and slow growing mass, as in our case. Facial paralysis is rare in WT,

attributed to secondary inflammation, fibrosis, metaplasia, or malignancy. In one of the studies, a patient with facial paralysis was reported.²

In the literature, the grades of mucoepidermoid carcinoma were as follows: 10 cases had low grade, 4 cases had intermediate grade, and 1 case had high-grade carcinoma. The pathologic examination of the specimens showed a low-grade mucoepidermoid cancer in our patient.

According to Seifert,⁸ the diagnosis of malignant transformation of WT is based on distinct criteria: (i) the presence of a preexisting benign WT; (ii) the presence of transitional zones from benign oncocytic to frankly malignant epithelia; (iii) the infiltrating growth in the surrounding lymphoid tissue; and (iv) the exclusion of metastases to the lymphoid stromal component of a primary extrasalivary tumor.¹² In our case, also, there was a benign WT component and transitional epithelium, which were between the malignant and benign epithelium. Infiltrating tumor islands showing glandular structures in the desmoplastic stroma in the lymphoid background were also seen. Another potential focal point was not defined radiologically and clinically.

Mucoepidermoid carcinoma in the WT of parotis should be differentiated from the following lesions. First,

WT is accompanied by metaplasia of squamous cells and mucous cells. Similar to the normal parotid gland, WT accompanied by focal squamous and mucous cells is not uncommon. A large area of squamous cell metaplasia was observed in ~7.5% of all WTs.² Normal epithelial tissues in Wartin tumor show a bilayered structure; abnormal structures and atypical cells are characterized by squamous and mucosal cell metaplasia, an increase in epithelial layers, and formation of mucus and cystic structures covered by intermediate cells. For this reason, it is difficult to determine the presence of malignant transformation. The main point of identification is the lack of metaplasia in atypical cells and infiltrative growth. In our case, there were a few cells showing squamous cells with orthochromatic nuclear features. Along the invasive areas, the tumor cells forming irregular glandular structures, extracellular mucin lakes, and solid areas were seen in the desmoplastic stroma and included atypical nuclear features such as hyperchromasia and evident mitotic activation.

Second, hyperplasia of stromal fibrous tissue and hyaline degeneration can be observed in mucoepidermoid cancer.¹⁰ It is difficult to distinguish the metaplastic mucosal epithelium of the Wartin tumor from the mucosal epithelium of the mucoepidermoid carcinoma on the basis of dysplasia. Patchy distribution of mucous glands, irregular gland structure, mucous lakes, mucus spillover, and cancer stroma suggested the possibility of mucoepidermoid cancer. In our case, there were similar difficulties, but infiltrative, growing, and atypical nuclear features suggested malignant epithelium.

Third, WT and mucoepidermoid cancer can develop independently and coexist.¹⁸ As in squamous cell carcinoma arising from WT, the mucoepidermoid carcinoma should be differentiated from another pattern of malignant transformation of WT. Squamous cell carcinoma, mucoepidermoid carcinoma, oncocytic carcinoma, undifferentiated carcinoma, and adenocarcinoma have been reported as arising within WT.³ Histopathologic findings and immunohistochemical findings may be helpful in distinguishing other tumors. We only used alcian blue and mucicarmine histochemical staining and Ki-67 for proliferation index, for the diagnosis of our case, because their histopathologic findings were not similar to other tumors.

Finally, tumor-to-tumor metastasis of lung and of renal carcinomas into WT, is a very rare condition, and should be distinguished. This can be excluded by physical and radiologic examinations. In our patient, no other tumor was demonstrated by radiologic or physical examination.

Cytogenetic and molecular analyses of mucoepidermoid carcinoma have identified some specific chromosomal translocations. The recurrent translocations of *t(11;19) (q21; p13)* and *t(11;15) (q21; q26)* result in novel fusion oncogenes, *CRTC1-MAML2* and *CRTC3-MAML2*, respectively. These fusion genes act as a transcription factor on the Notch and CREB regulatory pathway.¹⁸ This pathway plays a major role in tissue development, regulating cellular differentiation, survival, and/or proliferation. The *CRTC1-MAML2* and *CRTC3-MAML2* fusion transcripts are present in ~30% to 80% and 6% cases of mucoepidermoid carcinoma, respectively. Metaplastic Warthin-like tumors having *CRTC1/MAML2* fusion are more likely to be diagnosed as mucoepidermoid carcinoma due to the similar histologic features, whereas fusion negative ones are more likely to be diagnosed as WT due to the similar histologic features; for this reason, it can be used in differential diagnosis.¹⁸

Ultrasound is the main preferred method for detection of salivary gland tumors. USG can reveal whether the mass is part of the salivary gland or not, the parenchymal structure of the gland, the nature of the mass, and the presence of cervical and intraparotid lymph nodes, but, it has limitations in showing the location (in superficial or deep lobe) of the mass. The invasion of the bone tissue can be assessed by CT. MRI is the best diagnostic modality. Precontrast and postcontrast imaging play an important role in the evaluation of the tumor localization, and locoregional extension and facial nerve. In our case, after USG-guided fine needle biopsy was performed on the mass and the lymph node; the patient underwent total parotidectomy with preservation of the facial nerve.

Surgical resection is the main treatment of mucoepidermoid carcinoma in WT of the parotid gland. The prognosis depends largely on the tumor stage, tumor grade, and the adequacy of the resection margins. In high-grade mucoepidermoid carcinoma, adjuvant radiation therapy seems to aid in local control in cases of advanced staging, close or positive surgical margins, high-grade histology, perineural invasion, or lymphovascular invasion and lymph node metastasis.¹⁹ Low-grade disease is well controlled with complete surgical resection, with control reaching 85% at 10 years. Adjuvant RT generally is not indicated if adequate margins are obtained. Therefore, we preferred only surgery in the treatment of our case and did not administer radiotherapy.

Mucoepidermoid carcinomas are classified as high grade and low grade histologically. While the high-grade type is a highly aggressive tumor and makes early metastasis and local recurrence, its low-grade counterpart usually demonstrates a more benign nature and rarely metastasizes. Platinum-based chemotherapy is the standard option for these groups of patients.²⁰ With the knowledge that salivary gland carcinomas express various potential targets such as the epidermal growth factor receptor (EGFR), human epidermal growth factor receptor-2 (HER-2), and estrogen receptor β , many studies were conducted to investigate the efficacy of targeted therapies against these molecules. The patients with adenocystic carcinoma and nonadenocystic carcinoma were included in the studies. However, it is not possible to give a definite result due to the low number of cases with mucoepidermoid carcinoma. Further studies are needed to decide the efficacy of such targeted therapies.

In conclusion, mucoepidermoid carcinoma in WT of the parotis, which is not reported in the pediatric age group up to now, is very rare and should be taken into account in the differential diagnosis of parotid tumors.

REFERENCES

1. Rebours C, Couloigner V, Galmiche L, et al. Pediatric salivary gland carcinomas: diagnostic and therapeutic management. *Laryngoscope*. 2017;127:140-147.
2. Yu C, Song Z, Xiao Z, et al. Mucoepidermoid carcinoma arising in Warthin's tumor of the parotid gland: clinicopathological characteristics and immunophenotypes. *Sci Rep*. 2016;6:30149.
3. Williamson JD, Simmons BH, el-Naggar A, et al. Mucoepidermoid carcinoma involving Warthin tumor, a report of five cases and review of the literature. *Am J Clin Pathol*. 2000;14:564-570.
4. Jaramillo S, Rojas Y, Slater BJ, et al. Childhood and adolescent tracheobronchial mucoepidermoid carcinoma (MEC): a case-series and review of the literature. *Pediatr Surg Int*. 2016;32:417-424.

5. Smółka W, Markowski J, Piotrowska-Seweryn A, et al. Mucoepidermoid carcinoma in Warthin tumor of the parotid gland. *Arch Med Sci*. 2015;11:691–695.
6. Gnepp DR, Schroeder W, Heffner D. Synchronous tumors arising in a single major salivary gland. *Cancer*. 1989;63:1219–1224.
7. Gadiant SE, Kalfayan B. Mucoepidermoid carcinoma arising within a Warthin's tumor. *Oral Surg Oral Med Oral Pathol*. 1975;40:391–398.
8. Seifert G. Bilateral mucoepidermoid carcinomas arising in bilateral pre-existing Warthin's tumours of the parotid gland. *Oral Oncol*. 1997;33:284–287.
9. Saku T, Hayashi Y, Takahara O, et al. Salivary gland tumors among atomic bomb survivors, 1950–87. *Cancer*. 1997;79:1465–1475.
10. Nagao T, Sugano I, Ishida Y, et al. Mucoepidermoid carcinoma arising in Warthin's tumour of the parotid gland: report of two cases with histopathological, ultrastructural and immunohistochemical studies. *Histopathology*. 1998;33:379–386.
11. Curry JL, Petruzzelli GJ, McClatchey KD, et al. Synchronous benign and malignant salivary gland tumors in ipsilateral glands: a report of two cases and a review of literature. *Head Neck*. 2002;24:301–306.
12. Yamada S, Matsuo T, Fujita S, et al. Mucoepidermoid carcinoma arising in Warthin's tumor of the parotid gland. *Pathol Int*. 2002;52:653–656.
13. Martins C, Cavaco B, Tonon G, et al. A study of MECT1-MAML2 in mucoepidermoid carcinoma and Warthin's tumor of salivary glands. *J Mol Diagn*. 2004;6:205–210.
14. Mardi K, Sharma J. Mucoepidermoid carcinoma arising in Warthin's tumor: a case report. *Indian J Pathol Microbiol*. 2007;50:331–333.
15. Bell D, Luna MA, Weber RS, et al. CRTCl/MAML2 fusion transcript in Warthin's tumor and mucoepidermoid carcinoma: evidence for a common genetic association. *Genes Chromosomes Cancer*. 2008;47:309–314.
16. Mohapatra M, Satyanarayana S. Low grade mucoepidermoid carcinoma in a setting of Warthin's tumor. *Indian J Pathol Microbiol*. 2012;55:392–394.
17. Heatley N, Harrington KJ, Thway K. Warthin tumor-like mucoepidermoid carcinoma. *Int J Surg Pathol*. 2018;26:31–33.
18. Techavichit P, Hicks MJ, López-Terrada DH, et al. Mucoepidermoid carcinoma in children: a single institutional experience. *Pediatr Blood Cancer*. 2016;63:27–31.
19. Olsen MP, Mitchell AO, Miles EF. Postoperative radiation therapy for parotid mucoepidermoid carcinoma. *Case Rep Oncol Med*. 2014;2014:345128.
20. Alfieri S, Granata R, Bergamini C, et al. Systemic therapy in metastatic salivary gland carcinomas: a pathology-driven paradigm? *Oral Oncol*. 2017;66:58–63.