

Right atrial ball thrombus associated with atrial septal occluder device: A late complication of transcatheter atrial septal defect closure

In a large autopsy study, intracardiac ball thrombi are usually seen in the left atrium and rarely seen in the right atrium. They may be one or more in number. Right atrial ball thrombus may appear as a complication of central venous catheterization or be coexistent with tricuspid stenosis. A 42-year-old woman who began routine hemodialysis 5 years ago due to chronic kidney disease was admitted to our hospital because of dyspnea. She had undergone secundum atrial septal defect closure with Amplatzer septal occluder (ASO) device 7 years ago and had not received antiplatelet or anticoagulation therapy. She had a normal sinus rhythm. Her physical examination at admission revealed normal results, except for a thrill on the right wrist due to an arteriovenous fistula. Transthoracic echocardiography revealed a large, ball-like thrombus in the right atrium associated with the atrial septal occluder device (Fig. 1, Video 1). The thrombus was 22x22 mm in size, and the morphology of tricuspid valve was normal. The tricuspid regurgitation jet was moderate with a velocity of 3.6 m/s. No residual defect of the septal occluder device was observed. Computed tomography angiography was performed for pulmonary embolism screening, and subsegmental filling defects were detected. In addition, ball-like filling defect adjacent to the ASO device was clearly observed in the right atrium on computed tomography images (Fig. 2). To the best of our knowledge, this is the first case report of right atrial ball thrombus associated with the atrial septal occluder device.

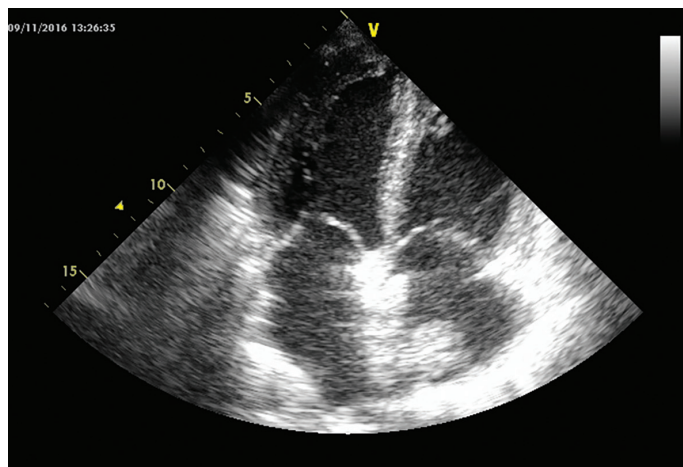


Figure 1. Two-dimensional apical four-chamber view showing the ball-like thrombus in the right atrium that is associated with the atrial septal defect closure device

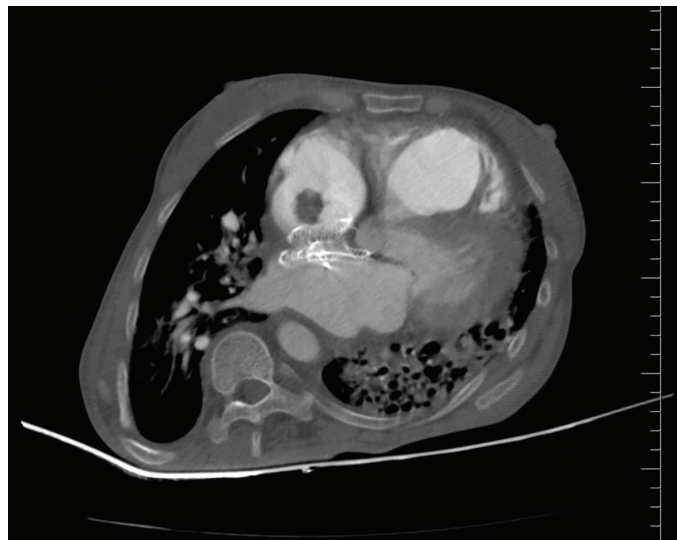


Figure 2. Computed tomography angiography of the thorax demonstrating the ball-like thrombus in the right atrium adjacent to the atrial septal defect closure device

Video 1. Transthoracic echocardiographic apical four-chamber view

Belma Kalaycı, Süleyman Kalaycı¹
Department of Cardiology, Faculty of Medicine, Bülent Ecevit University, Zonguldak- Turkey
¹**Department of Cardiology, Zonguldak Atatürk State Hospital, Zonguldak-Turkey**

Address for Correspondence: Dr. Belma Kalaycı
 Bülent Ecevit Üniversitesi, Tıp Fakültesi
 Kardiyoloji Anabilim Dalı
 67600, Zonguldak- Türkiye
 E-mail: drbelma@hotmail.com

©Copyright 2017 by Turkish Society of Cardiology - Available online at www.anatoljcardiol.com
 DOI:10.14744/AnatolJCardiol.2017.8012

Giant right coronary artery aneurysm mimicking sinus Valsalva aneurysm of the aorta

A 40-year-old male patient was admitted to a private hospital (Ortadoğu Hastanesi) with complaints of back pain and burning in the stomach for the last 6 months. His hematological examination and echocardiography findings were normal. Chest radiography revealed a bulge on the right side of the heart (Fig. 1). Computed tomography (CT) revealed a homogeneously enhanced cystic mass with a maximum diameter of 9 cm, which was adjacent to the aortic root and compressing over the superior vena cava, right atrium, and right ventricle (Fig. 2). CT findings were supported by echocardiography findings (Video 1).

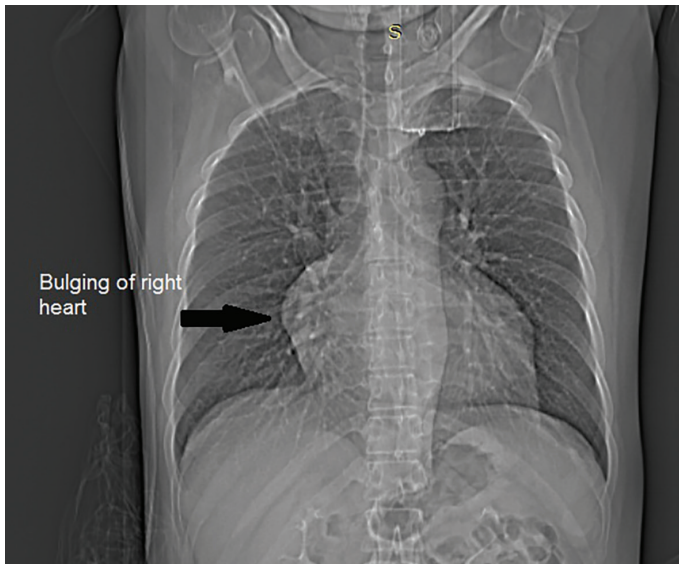


Figure 1. Chest radiography revealed a bulge on the right side of the heart.

Coronary angiography was performed for differential diagnosis; it revealed an aneurysmal sac filling with radiopaque material on the trace of the right coronary artery, indicating communication with the ascending aorta, and distal branches of the right coronary artery filling in the late phase of angiography; however, the left main coronary artery and its branches appeared normal.

Based on CT scan, echocardiography, and coronary angiography findings, differential diagnoses of sinus Valsalva aneurysm, aortic pseudoaneurysm, and right coronary artery aneurysm were made. The patient was admitted to our clinic and underwent urgent open-heart surgery for these preliminary diagnoses. After opening the mass, we observed a giant aneurysm arising from the proximal portion of the right coronary artery, and the inside of the pouch was covered with a thrombus (Video 2). Right coronary artery continuation was achieved with saphenous vein bypass after resecting the aneurysm. Pathological examination confirmed atherosclerotic aneurysm. The patient was discharged on the fifth day postoperatively.

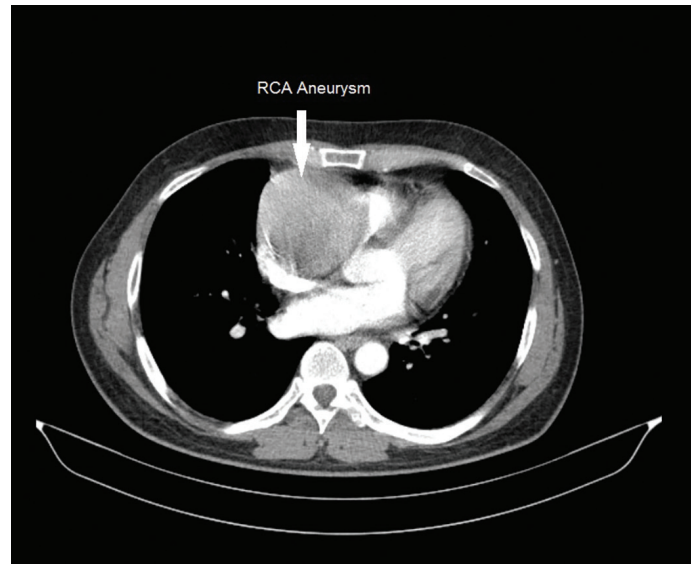


Figure 2. Computed tomography showed a cystic mass with a maximum diameter of 9 cm, which was adjacent to the aortic root and compressing over the superior vena cava, right atrium, and right ventricle.

Video 1. Transthoracic echocardiography demonstrated a 9-cm giant cystic mass adjacent to the lateral wall of the right heart.

Video 2. A giant aneurysm arising from the proximal portion of the right coronary artery can be observed, and the inside of the pouch was covered with a thrombus.

Nehir Sucu, Abdülkadir Bilgiç, Dilek Yılmaz*, Ayten Öztaş
Departments of Cardiovascular Surgery and *Cardiology, Faculty of Medicine, Mersin University, Mersin-Turkey

Address for Correspondence: Dr. Nehir Sucu
Mersin Üniversitesi Tıp Fakültesi Kalp ve Damar Cer Anabilim Dalı
Çiftlikköy 33343 Mersin-Türkiye
Phone +90 324 241 00 00/21684 Fax: +90 324 241 00 98
E-mail: nehirsucu@yahoo.com

©Copyright 2017 by Turkish Society of Cardiology - Available online at www.anatoljcardiol.com

DOI:10.14744/AnatolJCardiol.2017.8039