

UNUSUAL DONOR SITES FOR HARVESTING OF ISLAND SKIN GRAFTS

Gümüş N.

Plastic and Reconstructive Surgery Department, Adana Numune Research and Training Hospital, Adana, Turkey

SUMMARY. This study reports on the use of two unusual donor sites for the harvesting of island skin grafts used in the coverage of large skin wounds. Island grafts were taken not only from intact skin but also from itself and from newly generated epithelium, so that it could be transferred to another defect area. The study included 23 patients with skin wounds of different sizes due to burn injury (17 patients) and traffic accidents (6 cases). After granulation tissue had taken on the wound surface, island grafts (area 1 to 2 cm²) were harvested from three donor sites and placed over the wound 1 to 3 cm apart. The granulation tissue around the grafts was covered by the epithelium spreading from the island grafts, with the wounds closing in two to seven weeks, depending on their size. Donor areas healed spontaneously, with epithelialization in one to three weeks. Utilizing the new donor sites as a source of epithelium, island grafts may become a new alternative to other skin graft techniques in patients who have limited donor sites or who do not want any more donor site scars.

Introduction

Large wounds tend to lead to dangerous complications such as bacterial invasion, severe fluid and blood loss, and subsequent contracture resulting in certain functional impairments. Early wound closure - as soon as possible - is therefore mandatory to prevent such complications from occurring. This can sometimes be life-saving in severely burned patients. For the treatment of skin wounds, skin grafting is the most commonly used procedure, providing early, simple, and stable wound closure.

Nowadays, there are many kinds of skin grafting techniques, such as microskin graft, stamp skin graft, mesh graft, expanded graft, and skin soup graft, which have been described especially for the closure of large skin defects. However, in a small skin wound, coverage is simpler using either a piece of skin graft or a local flap. In the treatment of large wounds, all procedures aim to use a smaller area of skin graft than the size of the wound so that donor site requirements can be decreased by reducing the size of the graft needed.¹⁻⁴ Also, reduced donor site requirements lead to less donor site morbidity.

In this study, two unusual donor sites for the harvesting of island graft were used in the coverage of skin defects in patients with large wounds. Island grafts were taken not only from intact skin but also from itself and from newly generated epithelium so that it could be transferred to another defect area.

Patients and methods

This study included 23 patients who had large skin

wounds caused by burn injury (17 cases) and traffic accidents (6 cases). Their ages varied from 5 to 52 years, with an average of 22.4 years (*Figs. 1a, 2a*). Of the patients, seven were children; four patients were female. All the wounds were protected from bacterial infections by dressings with antibacterial agents and by removing necrotic tissues, with constant wound care. If there were any signs of invasive wound infection, intravenous antibiotherapy was started and continued until the infection subsided. When granulation tissue on the wound surface became sufficient to be grafted, patients were subjected to an operation in which an island graft was harvested from three donor sites (area, 1 to 2 cm²): either, first of all, from the anterior surface of the thigh as a split-skin graft; or, secondly, from newly epithelialized areas that were injured superficially in the same trauma and had already healed spontaneously without any need of surgery; or, thirdly, from previously used island grafts (*Figs. 1a, 1b, 2b*). The grafts were then implanted on the wound surface at a distance of 1-3 cm from each other and dressed with an ointment including an antibacterial agent (*Figs. 1c, 2c*). The first dressing was changed five days post-graft, after which they were changed regularly every other day.

Already used island grafts harvested as split-skin grafts in previous operations were transferred from their site to another defect area on day 7 after the first implantation (*Figs. 1b, 1c*). Some of these were used in the same way twice for the closure of another area in the same wound or in a skin defect located in a separate anatomical region. As the island grafts were placed 1 to 3 cm from each other, the granulation tissue around the grafts was covered by of the epithelium spreading from the island grafts (*Figs. 1b, 2d*).

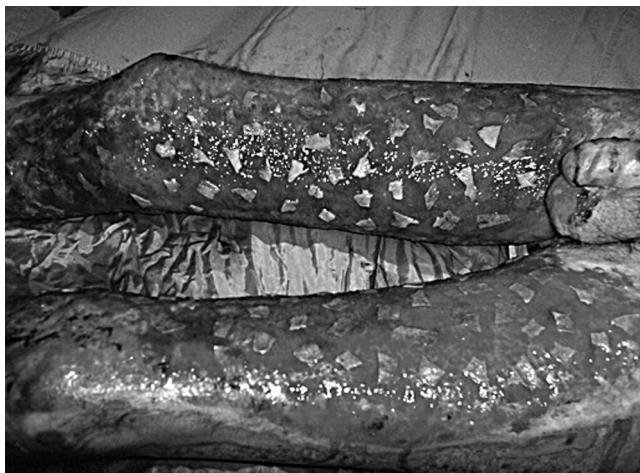

Fig. 1a - Intra-operative view of burn patient with split-thickness island grafts taken from lateral surface of thigh and placed on wound surface.

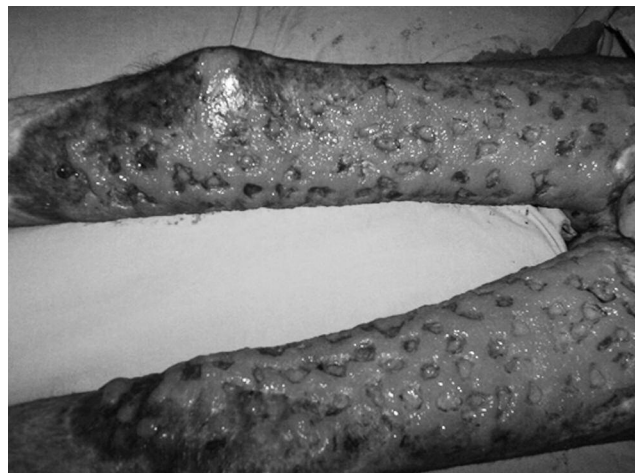

Fig. 1b - Epithelialization spreading on wound surface. Note that most of the island grafts were taken from their sites for transfer to the posterior surface of the lower extremity.

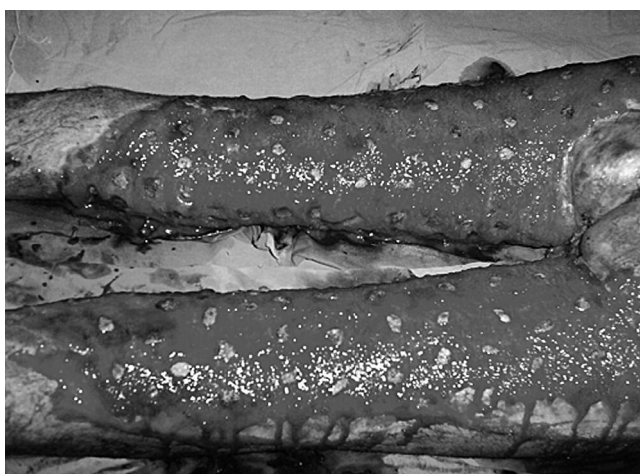


Fig. 1c - Re-implanted grafts harvested from already used island grafts on the anterior surface of the extremity.

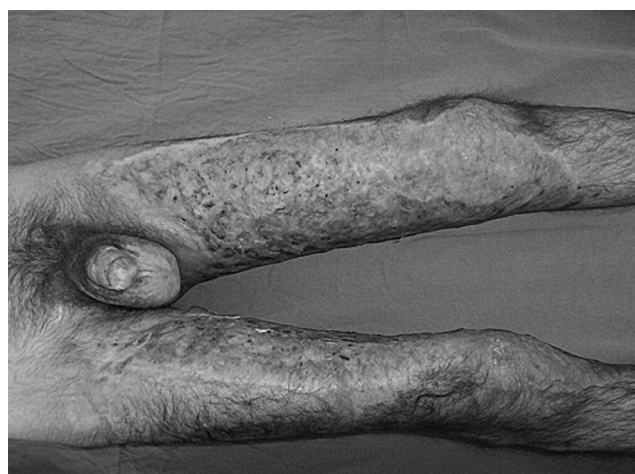

Fig. 1d - Late results of lower extremity defect closed by the epithelialization generated by island grafts.

Results

As in eight patients all the island grafts used for coverage of the wounds were harvested from newly generated epithelium, no other donor sites were required and no scar was left on the intact skin of the body. All the wounds were covered by spreading of the epithelium in two to seven weeks, depending on their size (Figs. 1d, 2e). The patient with the biggest wound (40% TBSA burned) healed in seven weeks, while the smallest skin defect in the study, namely a scalp wound suffered in a road accident, healed in just two weeks. Donor areas healed in one to three weeks. However, some of the grafts were lost while dressings were being changed because of mechanical traumas. Island grafts in particular, taken from new epithelium, were

very susceptible to mechanical injury - the first dressing should be changed on day 5 after the operation to prevent any damage being done to the island grafts. The other cause of graft loss was lysis due to infection. Although some grafts taken from epithelium initially appeared on examination to be lost, epithelialization developed within two weeks. Regrafting with an island graft over lost graft areas, if necessary, was likewise facilitated by using local anaesthesia during wound dressing. Also, in 14 cases, local anaesthesia supported by intravenous sedation was enough to provide a painless surgical intervention in the primary surgery.

In the follow-up, ranging between 3 and 35 months (average, 9 months), although physiotherapy was performed to prevent contracture and stiffness of the joints, in five

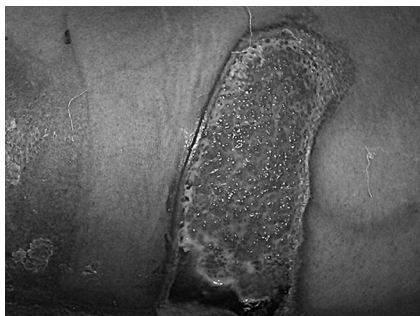

Fig. 2a - Skin defect in lumbar area due to burn injury.



Fig. 2b - Same patient, elliptically-shaped island graft taken from superficially burned and healed area.

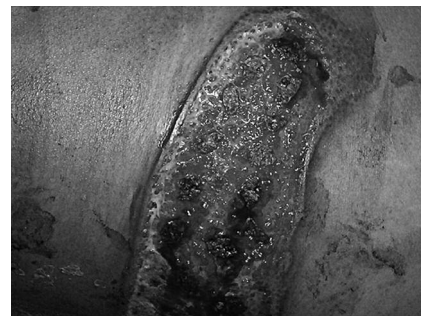

Fig. 2c - Island grafts on wound.

patients contractures developed after wound healing and surgical intervention was needed. Pressure garments were used in all patients to prevent hypertrophic scar formation.

With regard to donor site morbidity, this was not observed in patients whose island grafts were taken only from new epithelium and older grafts while scars remained in patients whose grafts were harvested as split-skin grafts from intact skin, a well-known donor site morbidity. In some patients donor site scars were reduced in dimension thanks to the use of new epithelium and older graft in the same patient. In one patient there was some hypertrophy in the donor site. A “cobblestone” appearance was another important outcome occurring after healing of the wound surface in 10 patients, which was not cosmetically acceptable; however, the wound coverage was stable and soft (*Fig. 1d*).

Discussion and conclusions

Island grafts have been demonstrated to be suitable for a number of purposes such as closing skin defects, studying skin regeneration in isolation from other processes, and isolating skin regeneration from spontaneous processes of wound closure.⁵⁻⁷

Orgill⁵ emphasized that the island graft was a simple method for demonstrating the effect of epithelial derivatives on wound regeneration, without using sophisticated biological or genetic markers, and that it permitted observation of test material within the wound without interference from the periphery until wound contracture and epithelialization of the surrounding skin encroached upon the study area. This was an interesting approach to the island graft used for experimental purposes - our study, unlike that of Orgill, included a clinical experience of the island graft

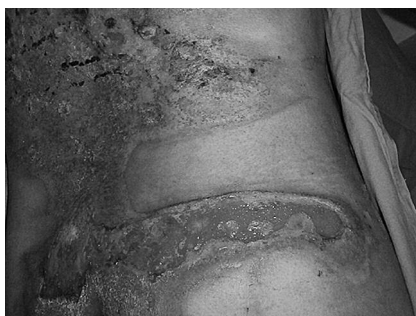

Fig. 2d - Island grafts and donor site on day 6 after operation.

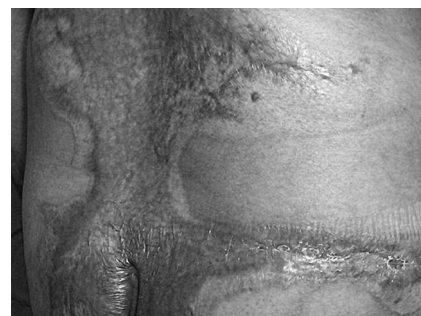

Fig. 2e - Late view of wound. Note some scar hypertrophy.

for closing skin wounds, taking it from unusual donor sites.

Another experimental study that aimed to isolate skin regeneration from spontaneous processes of wound closure, using island grafts in guinea pigs, concluded that island grafting allowed the study of early events in skin regeneration in isolation from epithelialization, contracture, and scar synthesis.⁶

The use of island grafts in the closure of surgical wounds after the excision of cutaneous malignancies has been described, and the classification of island grafts was performed on the basis of the shape of the primary defect and of the partial closure and on whether the graft or grafts were distant or contiguous.⁷ It was emphasized that the techniques for the use of island grafts in the closure of surgical wounds were quite simple and yielded good cosmetic results. In the present study, as the patients had skin wounds due to burn injuries and traffic accidents, the results were quite different from those seen in surgical wounds caused by the excision of cutaneous malignancies. Both very large skin defects and small skin wounds, e.g. surgical wounds, were treated successfully with island grafts. Additionally, grafts were taken not only from the anterior surface of the thigh or near the wounds, as in the other research, but also from the new epithelium and the older island grafts.

The cobblestone appearance, or wound scar remaining after grafting, was not cosmetically acceptable, but the donor site scar was good. As is known, this appearance has been observed in burn patients after the healing of microskin grafting and, when treated cosmetically, it was found to provide relatively poor results.^{1,4,8}

The main purpose of skin defect coverage, especially in extensive wounds, is to use a smaller skin graft than the defect size, which is very important in patients presenting limited skin graft donor sites, because in the course of wound healing chronically open wounds may lead to severe life-threatening problems. However, in small wounds, taking a skin graft leaves a scar, so the more is harvested, the larger the scar is, which is cosmetically un-

desirable. It should be emphasized that utilizing new donor sites in order to harvest island grafts creates a source of epithelium - in some cases they can be used both as skin grafts and as donor sites that economize on the skin graft, providing less or no donor site scar and decreasing the necessity of skin grafting.

As clinical studies on island grafts used for wound coverage are very limited in the literature, these outcomes can be considered to be promising as regards the extensive use of island grafts with new donor sites as either a primary or a secondary grafting technique combined with other methods of skin grafting in wound closure. These new donor sites may encourage further studies covering a larger number of cases.

RÉSUMÉ. Cette étude décrit l'emploi de deux sites donateurs de peau inusuels pour le recueil de greffes de peau en îlot pour la couverture de lésions cutanées de grande extension. Les greffes en îlot ont été prises non seulement de la peau intacte mais aussi de la greffe elle-même et de l'épithélium récemment généré pour être transféré dans une autre zone lésée. L'étude inclut 23 patients atteints de lésions cutanées de diverse extension provoquées par des brûlures (17 cas) et par des accidents de la route (6 cas). Après la prise du tissu de granulation sur la surface de la lésion, des greffes en îlot (diamètre, 1 à 2 cm²) ont été recueillies de trois sites donateurs et posées sur les lésions à une distance d'un à trois centimètres l'une de l'autre. Le tissu de granulation autour des greffes a été couvert en répandant l'épithélium des greffes en îlot, obtenant la fermeture des lésions dans une période de deux à sept semaines, selon les dimensions. Les zones donatrices sont guéries spontanément, avec l'épithélialisation dans une période d'une à trois semaines. Avec l'emploi de ces nouveaux sites donateurs comme source de l'épithélium, les greffes en îlot peuvent devenir une nouvelle alternative aux autres techniques de greffe de peau dans les patients qui présentent des sites donateurs limités ou qui ne désirent pas avoir d'autres cicatrices dans les sites donateurs.

BIBLIOGRAPHY

1. Lin T.W., Horng S.Y.: A new method of microskin mincing. *Burns*, 20: 525-28, 1994.
2. Kreis R.W., Mackie D.P., Vloemans A.W., Hermans R.P., Hoekstra M.J.: Widely expanded postage stamp skin grafts using a modified Meek technique in combination with an allograft overlay. *Burns*, 19: 142-5, 1993.
3. Varma S.K., Henderson H.P., Hankins C.L.: Calcium alginate as a dressing for miniskin grafts (skin soup). *Br. J. Plast. Surg.*, 44: 55-6, 1991.
4. Zhang M.L., Chang Z.D., Wang C.Y. et al.: Microskin grafting in the treatment of extensive burns: A preliminary report. *J. Trauma*, 28: 804-8, 1988.
5. Orgill D.P., Butler C.E.: Island grafts: A model for studying skin regeneration in isolation from other processes. *Adv. Biochem. Eng. Biotechnol.*, 93: 161-72, 2005.
6. Orgill D.P., Yannas I.V.: Design of an artificial skin. IV. Use of island graft to isolate organ regeneration from scar synthesis and other processes leading to skin wound closure. *J. Biomed. Mater. Res.*, 39: 531-5, 1998.
7. Cronin T.A., Cronin T.A., jr: A classification of the island grafts. *Dermatol. Clin.*, 13: 483-98, 1995.
8. Çoban Y.K., Gümüş N.: Reuse of skin graft patches for the coverage of skin defects. *Burn Care and Research*, 27: 234-6, 2006.

This paper was received on 1 September 2008.

Address correspondence to: Dr Nazım Gümüş, Mahfasıgmaz mah. 85 sok. Burkent sitesi A blok Kat. 4, No. 8, Adana, Turkey. Tel.: 0090 322 2332989; e-mail: gumus1970@hotmail.com