



Update on the novel management and future paternity situation in adolescents with varicocele

Selahittin Çayan, Murat Bozlu, Erdem Akbay

Cite this article as: Çayan S, Bozlu M, Akbay E. Update on the novel management and future paternity situation in adolescents with varicocele. Turk J Urol 2017; 43: 241-6

ABSTRACT

Varicocele is a progressive disease, and the incidence of varicocele and varicocele related testicular hypotrophy increases with puberty. This review updates novel management and future paternity potential in adolescents with varicocele. Main goal of treatment of the adolescent varicoceles is preservation of fertility. Current recommendations for adolescent varicocele repair are testicular hypotrophy (>2 mL or >20%) on the affected side and/or impaired spermatogenesis in the post-pubertal period. The best treatment modality for adolescent varicocele should include elimination of the varicocele with lower complication rates. Microsurgical varicocelectomy techniques have been shown to result in fewer recurrences and postoperative complications than conventional varicocelectomy in adolescents. We conducted a meta-analysis, including 2 studies with the control groups, and reporting paternity situation after varicocele treatment. In this meta-analysis, varicocele repair increases paternity rate 2.42 times with a p value of 0.000. Adolescents with varicocele and their families should be counselled in the light of these findings.

Keywords: Adolescents; fertility; microsurgery; paternity; varicocele

Introduction

Varicocele is a surgically correctable and the most commonly seen urogenital abnormality in adolescents.^[1] The prevalence of varicocele is 6-8% in 11-14, and 11-19% in 15-19 year-old individuals.^[2,3] Varicocele-related testicular hypotrophy can be seen in 7.3%, and 9.3% of the boys with varicocele aged 11-14, and 15-19 years, respectively while this pathology is not present in individuals aged under 11 years.^[2] In a meta-analysis, including 20 studies, it has been indicated that the presence of varicocele in youth negatively affects sperm density, motility and morphology, and treatment appears to result in moderate improvement in sperm density and mild improvement in sperm motility.^[4] The incidence of bilateral varicoceles has been reportedly higher in the recent papers than in the previous studies in the literature. These findings support that varicocele is a progressive disease and the incidence of varicocele and varico-

cele-related testicular hypotrophy increases in puberty.

This review updates novel management and future paternity potential in adolescents with varicocele. We also report outcomes of a meta-analysis of the 2 studies with the control groups, reporting paternity status after varicocele treatment.

Diagnosis of adolescent varicocele

Adolescent varicoceles are usually asymptomatic, and may be incidentally detected by routine physical examination or recognized by their families. Although varicocele may be diagnosed during physical examination, scrotal color Doppler ultrasound, thermography and venography, physical examination is the reference standard for the diagnosis of adolescent varicoceles.^[5-8] Additional radiologic imaging is unnecessary to diagnose subclinical varicocele in the adolescents, because the

Department of Urology, Mersin University School of Medicine, Mersin, Turkey

Submitted:
10.07.2017

Accepted:
19.07.2017

Correspondence:
Selahittin Çayan
E-mail:
selcayan@hotmail.com

©Copyright 2017 by Turkish Association of Urology

Available online at
www.turkishjournalofurology.com

significance of subclinical varicocele remains uncertain. Only a varicocele detected by physical examination should be considered potentially significant. However, varicoceles should be confirmed with color Doppler ultrasound according to EAU guidelines.^[9] In addition, diagnostic imaging may be necessary in the case of unilateral right, non-reducing varicocele, which may represent a silent retroperitoneal pathology.^[3] Boys should be examined in a warm room in the supine and standing positions with and without Valsalva maneuver. On physical examination, varicoceles are classified as grade 1 (palpable only during Valsalva maneuver), grade 2 (palpable without Valsalva maneuver) or grade 3 (visible without the need for palpation).^[17]

Testicular volume measurements are important in determining the need for adolescent varicocele surgery and also in following patients after varicocele repair. Although, there are some conflicting results in comparison of orchidometer and ultrasonography, testicular volumes may be measured with an orchidometer (Prader and Takihara/Rochester) and scrotal ultrasonography.^[3,5,8,9] If the discrepancy in testicular volumes is more than 2 mL or more than 10-20% difference on the affected side, then testicular hypotrophy is taken into consideration.

Serum follicle stimulating hormone (FSH), testosterone and semen analysis may be obtained in adolescents with Tanner stage 5 who might ejaculate.^[10-14] Semen analysis should be performed according to World Health Organization criteria.^[15] These tests should be requested from older adolescents with Tanner stage 5 who have a large varicocele and equal-sized testes (level of evidence 3).^[3]

Indications for varicocele repair

Testicular function is negatively affected by varicoceles in adolescents. Reduced sperm motility, increased number of abnormal forms and increased DNA fragmentation have been associated with varicocele. Nearly two-thirds of Tanner V boys with an uncorrected varicocele and normal testicular volumes achieve a normal total motile sperm count regardless of varicocele grade or age. Despite Tanner V development, 47% of the individuals with an initial poor semen quality will improve to normal status without surgery.^[10] Current recommendation is that varicocele should be treated at an early age, possibly because the testis is still developing at that age.^[9,11-14,16,17] The main goal of treatment of the adolescent varicoceles is preservation of fertility. Current recommendations for adolescent varicocele repair are based on the findings of impaired testicular growth and/or spermatogenesis. Absolute indication for varicocele repair is testicular hypotrophy (>2 mL or >20%) on the affected side (Level of evidence 2). Relative indications for varicocele repair are soft testis, bilateral large varicocele without testicular hypotrophy, presence of varicocele in a solitary testis, pain or discomfort secondary to the varicocele, and poor semen quality in a Tanner stage 5 patients.

^[17] Some groups have also reported that it is best to operate early when the indications are appropriate such as a PRF of 38 cm/s or greater, the presence of 15% or 20% asymmetry or greater, or total testicular volume is low for a particular Tanner stage.^[8]

Treatment options for adolescent varicocele

To date, there have been no randomized, controlled, prospective clinical studies that compare the various techniques so as to describe the best method for the treatment of adolescent varicocele. Adolescent varicocele may be treated with many different modalities including radiologic, laparoscopic and open surgical approaches.^[3,14,18,19] The best treatment modality for adolescent varicocele should include elimination of the varicocele with lower complication rates. Therefore, the ideal technique should aim ligation of all internal and external spermatic veins with preservation of spermatic arteries and lymphatics. Radiologic embolization or sclerotherapy of spermatic veins appears to be a minimally invasive procedure. However, it has an interventional failure rate up to 15% of the cases, and needs sufficient skill and experience. In a multicentric, retrospective study in the United States, 1036 boys with varicocele had undergone open (n=405), laparoscopic (n=530) and percutaneous embolization (n=101) treatment by 213 physicians.^[18] Re-treatment rates were reported as 1.5% in the open surgery, 3.4% in the laparoscopic treatment and 9.9% in the embolization treatment. The incidence of hydrocele was 4.9, 8.1 and 5%, respectively. The high retroperitoneal (Palomo), radiologic and laparoscopic approaches can be performed for internal spermatic vein ligation.^[14,20-22] The inguinal (Ivanissevich) and subinguinal approaches can be also used to ligate the external spermatic veins. Conventional varicocelectomy performed without optical magnification may miss smaller internal spermatic veins that may dilate in the future and cause recurrence. The use of microscopic magnification allows identification of the testicular artery, lymphatics and small venous channels. Therefore, microsurgical method results in a significant decrease in the incidence of hydrocele formation, testicular artery injury and varicocele recurrence.

Table 1 shows outcomes of varicocele treatment in pediatric population in the literature. Although most of varicocelectomy methods result in similar short term results, open microsurgical inguinal or subinguinal varicocelectomy techniques have been shown to result in fewer recurrences and postoperative complications than conventional varicocelectomy in adults (Level of evidence 2; grade B recommendation).^[9,17,23]

Another important consideration regarding varicocelectomy techniques in adolescents is future vasectomy.^[24] Vasectomy in men who underwent mass ligation varicocelectomy is likely to result in testicular atrophy. Therefore, this is another reason to choose an artery-sparing varicocelectomy technique in adolescents because vasectomy is the most common contraception method in men.

Table 1. Outcomes of the techniques for varicocele treatment in the literature

Techniques	Artery sparing	Hydrocele	Recurrence	Morbidity	Re-operation
Retroperitoneal	No	1-24%	0-18%	No	4-8%
Macroscopic inguinal	No	3-32%	12-15%	No	3.4%
Laparoscopic	Yes	2-12%	1-15%	Yes	2-4%
Radiologic	Yes	0-5%	15-25%	Yes	5-9.9%
Microsurgical	Yes	0-3%	0-3%	Yes	0-0.1%

Table 2. Paternity rates after varicocele repair in the literature

Studies	Year	Varicocele repair group		Control group		p
		n	Paternity rate	n	Paternity rate	
Salzhauer et al. ^[30]	2004	18	18/18 (100%)	∅		
Pajovic and Radojevic ^[31]	2013	16	12/16 (75%)	∅		
Bogaert et al. ^[32]	2013	86	67/86 (78%)	72	61/72 (85%)	>0.05
Çayan et al. ^[33]	2017	286	221/286 (77.3%)	121	59/122 (48.4%)	<0.005

Complications after varicocele repair

Postoperative complications vary with surgical techniques (Table 1). Recurrences after varicocele repair reportedly range between 0, and 25% varying with varicocelectomy techniques used.^[19,14,23,25-27] Postoperative hydrocele in adolescents is a potential problem with the incidence ranging between 0, and 32%. Other complications include wound infection, testicular atrophy and ilio-inguinal nerve damage.

Postoperative results

As is reported in the literature, varicocele repair has resulted in a significant increase in testicular volumes and consistency, and testicular catch-up growth has occurred in 53-94% of adolescents, postoperatively.^[28,29] However, testicular volumes may not increase significantly after varicocele repair in patients aged >14 years.^[13]

Studies suggest that varicocele repair in the adolescents significantly increases sperm parameters including sperm concentration, sperm motility and total motile sperm count, postoperatively. In addition to sperm parameters, varicocele repair probably has positive effects on Leydig cell function by improving serum testosterone level.^[25]

Postoperative follow-up

Boys undergoing varicocele repair should be followed with physical examination for postoperative complications such as recurrence, hydrocele formation and testicular atrophy firstly one month after the surgery, then every 3 months for the first year of postoperative period, then once a year (Figure 1). In addition to physical examination, testicular volumes should be

measured yearly. Annual semen analyses may be obtained in adolescents with Tanner stage 5.

Paternity situation after treatment of adolescent varicocele

Although varicocele is a progressive disease and leads to testicular atrophy in adolescents, to date, in the literature, only 4 studies have reported the effects of varicocele repair on later fertility, and the outcomes have been controversial (Table 2).^[30-33] Salzhauer et al.^[30] reviewed paternity status, using a questionnaire, in 43 responded adolescents who underwent varicocele surgery with Ivanissevich or Palomo technique. They found paternity rate as 100%. Pajovic and Radojevic^[31] reported paternity rate of 75% of 23 adolescents who underwent laparoscopic varicocelectomy. However, both studies lacked control group under conservative treatment. In a recent study by Bogaert et al.^[32], conducted with 661 adolescents, 372 underwent ante-grade sclerotherapy as the treatment group, and 289 had not received any treatment as the control group. Among 158 men who had an active desire to have a child, they found paternity rate as 79% in the treated group and 85% in the control group. Therefore, they concluded that pubertal screening and treatment of varicocele have no beneficial effect, regarding chance of paternity later in life. However, they excluded boys with bilateral or unilateral varicoceles, and only included radiologic treatment which has higher recurrence and technical failure rate, and the study did not report long-term complication rates. Çayan et al.^[33] reported 408 boys with clinical palpable varicoceles. Two hundred and eighty-six boys had microsurgical subinguinal or inguinal varicocele repair, and 122 boys had been followed up using conservative methods only. The paternity rates were found to be 77.3% in the microsurgical treatment, and 48.4%

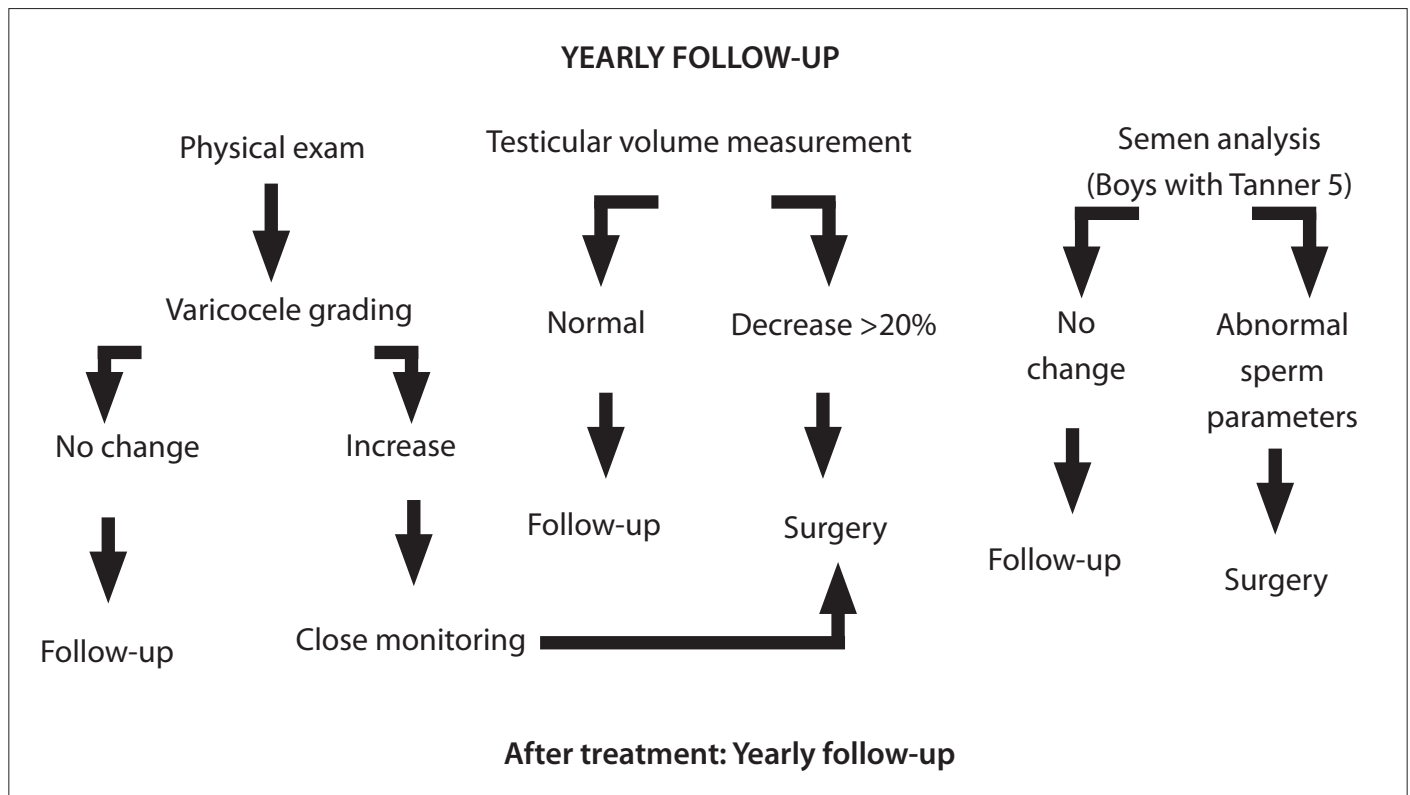


Figure 1. Algorithm for follow-up and treatment of adolescent varicocele

in the control groups, revealing a significant intergroup difference. In addition, microsurgical varicocele repair significantly decreased mean time to conception (11.18 ± 6.5 months), compared to the controls (16.85 ± 6.9 months). Boys with varicocele who had undergone microsurgical varicocele repair had higher sperm parameters and 3.63 times higher paternity chance than the controls who had not undergone varicocele surgery and followed up conservatively.

We conducted a meta-analysis of the 2 studies with the control groups, reporting paternity status after varicocele treatment.^[32,33] As this meta-analysis revealed varicocele repair increased paternity rate 2.42 times with a p value of 0.000 (Figure 2). Adolescents with varicoceles and their families should be fully informed in the light of these findings.

In conclusion, physical examination is the reference standard to diagnose adolescent varicoceles (grade A). Additional radiologic imaging is unnecessary to diagnose subclinical varicocele in the adolescents, because only a varicocele detected by physical examination should be considered potentially significant (grade B).^[1,3]

Testicular volume measurements are important in determining the need for adolescent varicocele surgery and also in following patients after varicocele repair. Testicular volumes may be mea-

sured with an orchidometer (Prader, Takihara and Rochester) and scrotal ultrasonography (grade B). If discrepancy between both testicular volumes is more than 2 mL or more than 10-20% against the affected side, then testicular hypotrophy should be taken into consideration (grade C).^[1,3]

The main goal of treatment of the adolescent varicoceles is preservation of fertility. Treatment should be offered to the adolescents with decreased testicular volume, while follow-up should be continued in the adolescents without testicular hypotrophy on the affected side (grade A). Postpubertal boys with varicocele should be followed with semen analysis, annually, and early treatment should be considered when there is an evidence of deterioration in sperm parameters, low serum testosterone and/or elevation of serum FSH levels (grade C).

Adolescent varicocele may be treated with many different modalities including radiologic, laparoscopic and open surgical approaches. The best treatment modality for adolescent varicocele should include elimination of the varicocele with lower complication rates (grade B). Studies support that the use of microscopic magnification allows identification of the testicular artery, lymphatics and small venous channels, resulting in a significant decrease in the incidence of hydrocele formation, testicular artery injury and recurrence of varicocele (grade B).

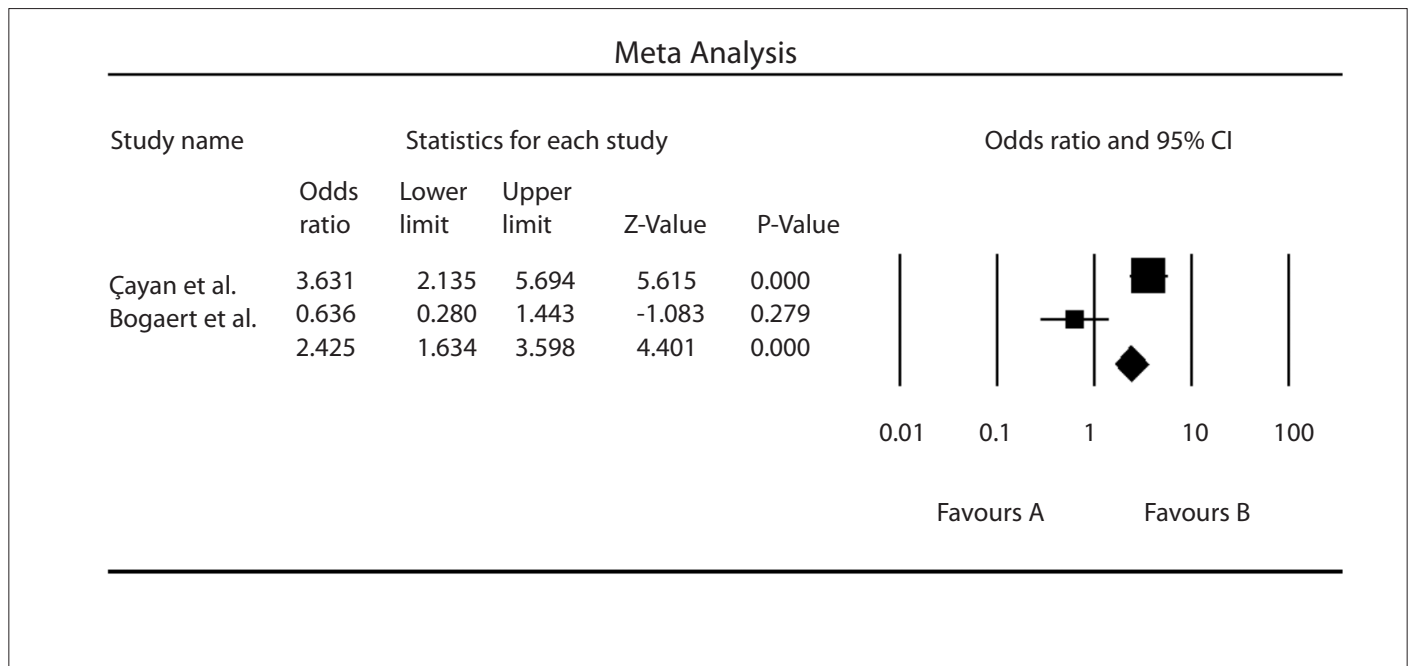


Figure 2. A meta-analysis of the 2 studies with the control groups, reporting paternity rates after varicocele repair^[32,33]

Varicocele repair results in a significant increase in testicular volumes and consistency, and testicular catch-up growth has been occurred in 53-94% of adolescents, postoperatively.^[28,29] However, testicular volumes may not increase significantly after varicocele repair in patients aged >14 years (grade C). Repair of the adolescent varicocele may improve semen parameters and serum hormone values regardless of testicular volumes (grade C).

Microsurgical varicocele repair in adolescents with varicocele significantly increases paternity rates and decreases time to conception and necessity of additional treatment to conceive after the surgery.^[33] Boys with varicocele who underwent varicocele repair will have 2.42 times higher paternity chance than the controls who had not received varicocele treatment and followed up conservatively. Adolescents with varicocele and their families should be informed in the light of these recommendations.

Peer-review: This manuscript was prepared by the invitation of the Editorial Board and its scientific evaluation was carried out by the Editorial Board.

Author Contributions: Concept - S.Ç., M.B., E.A.; Design - S.Ç., M.B., E.A.; Supervision - S.Ç., E.A., M.B.; Resources - S.Ç., M.B., E.A.; Materials - S.Ç., M.B., E.A.; Data Collection and/or Processing - S.Ç., E.A., M.B.; Analysis and/or Interpretation - S.Ç., E.A., M.B.; Literature Search - S.Ç., M.B., E.A.; Writing Manuscript - S.Ç., M.B., E.A.; Critical Review - S.Ç., M.B., E.A.

Conflict of Interest: No conflict of interest was declared by the authors.

Financial Disclosure: The authors declared that this study has received no financial support.

References

1. Çayan S, Woodhouse C. The treatment of adolescents presenting with a varicocele. *BJU Int* 2007;100:744-7. [\[CrossRef\]](#)
2. Akbay E, Çayan S, Doruk E, Duce M, Bozlu M. The prevalence of varicocele and varicocele-related testicular atrophy in Turkish children and adolescents. *BJU Int* 2000;86:490-3. [\[CrossRef\]](#)
3. Higuchi Ty, Holmdahl G, Kaefer M, Koyle M, Wood H, Woodhouse C, et al. International Consultation on urological diseases: congenital anomalies of the genitalia in adolescence. *Urology* 2016;94:288-310. [\[CrossRef\]](#)
4. Nork JJ, Berger JH, Crain DS and Christman MS. Youth varicocele and varicocele treatment: a meta-analysis of semen outcomes. *Fertil Steril* 2014;102:381-7. [\[CrossRef\]](#)
5. Çayan S, Akbay E, Bozlu M, Doruk E, Yıldız A, Acar D, et al. Diagnosis of pediatric varicoceles by physical examination and ultrasonography and measurement of the testicular volume using the Prader orchidometer versus ultrasonography. *Urol Int* 2002;69:293-6. [\[CrossRef\]](#)
6. World Health Organization: Comparison among different methods for the diagnosis of varicocele. *Fertil Steril* 1985;43:575-9.
7. Dubin L, Amelar RD. Varicocele size and results of varicocelectomy in selected subfertile men with varicocele. *Fertil Steril* 1970;21:606-19. [\[CrossRef\]](#)
8. Glassberg KI. My indications for treatment of the adolescent varicocele (and why?). *Trans Androl Urol* 2014;3:402-12.
9. Jungwirth A, Diemer T, Dohle GR, Giwercman A, Kopa Z, Krausz C, et al. EAU Guidelines of Male Infertility; the 2016 update. Available from: <https://uroweb.org/wp-content/uploads/EAU-Guidelines-Male-Infertility-2016>.

10. Chu DI, Zderic SA, Shukla AR, Srinivasan AK, Tasian GE, Weiss DA, et al. The natural history of semen parameters in untreated asymptomatic adolescent varicocele patients: A retrospective cohort study. *J Pediatr Urol* 2017;13:77.e1-77.e5. [\[CrossRef\]](#)
11. Çayan S, Akbay E, Bozlu M, Doruk E, Erdem E, Acar D, et al. The effect of varicocele repair on testicular volume in children and adolescents with varicocele. *J Urol* 2002;168:731-4. [\[CrossRef\]](#)
12. Lenzi A, Gandini L, Bagolan P, Nahum A, Dondero F. Sperm parameters after early left varicocele treatment. *Fertil Steril* 1998;69:347-9. [\[CrossRef\]](#)
13. Okuyama A, Nakamura M, Namiki M, Takeyama M, Utsunomiya M, Fujioka H, et al. Surgical repair of varicocele at puberty: a preventive treatment for fertility improvement. *J Urol* 1991;146:199-204.
14. Çayan S, Acar D, Ülger S, Akbay E. Adolescent varicocele repair: long-term results and comparison of surgical techniques according to optical magnification use in 100 cases at a single university hospital. *J Urol* 2005;174:2003-6. [\[CrossRef\]](#)
15. World Health Organization. *Laboratory Manual for the Examination of Human Semen and Semen-Cervical Mucus Interaction*, 5th ed. New York: Cambridge University Press; 2010.
16. Paduch DA, Niedzielski J. Repair versus observation in adolescent varicocele: a prospective study. *J Urol* 1997;158:1128-32. [\[CrossRef\]](#)
17. Rogue M, Esteves SC. A systematic review of clinical practice guidelines and best practice guidelines and best practice statements for the diagnosis and management of varicocele in children and adolescents. *Asian J Androl* 2016;18:262-8. [\[CrossRef\]](#)
18. Lurvey R, Durbin-Johnson B, Kurzrock EA. Adolescent varicocele: A large multicenter analysis of complications and recurrence in academic programs. *J Pediatr Urol* 2015;11:186.e1-6.e6. [\[CrossRef\]](#)
19. Çayan S, Kadioğlu TC, Tefekli A, Kadioğlu A, Tellaloğlu S. Comparison of results and complications of high ligation surgery and microsurgical high inguinal varicocelectomy in the treatment of varicocele. *Urology* 2000;55:750-4. [\[CrossRef\]](#)
20. Mazzoni G, Fiocca G, Minucci S, Pieri S, Paolicelli D, Morucci M, et al. Varicocele: a multidisciplinary approach in children and adolescents. *J Urol* 1999;162:1755-7. [\[CrossRef\]](#)
21. Kocvara R, Dvoracek J, Sedlacek J, Dite Z, Novak K. Lymphatic sparing laparoscopic varicocelectomy: a microsurgical repair. *J Urol* 2005;173:1751-4. [\[CrossRef\]](#)
22. Kass EJ, Marcol B. Results of varicocele surgery in adolescents: a comparison of techniques. *J Urol* 1992;148:694-6. [\[CrossRef\]](#)
23. Tekgul S, Dogan HS, Erdem E, Hoebeke P, Kocvara R, Nijman JM, et al. EAU Guidelines on Paediatric Urology 2015: European Association of Urology and European Society of Paediatric Urology. Available from: <http://www.uroweb.org/guideline/paediatric-urology>.
24. Goldstein M. Editorial: Adolescent varicocele. *J Urol* 1995;153:484. [\[CrossRef\]](#)
25. Çayan S, Kadioğlu A, Orhan I, Kandirali E, Tefekli E, Tellaloğlu S. The effect of microsurgical varicocelectomy on serum follicle stimulating hormone, testosterone and free testosterone levels in infertile men with varicocele. *BJU Int* 1999;84:1046-9. [\[CrossRef\]](#)
26. Misseri R, Gershbein AB, Horowitz M, Glassberg KI. The adolescent varicocele. II: the incidence of hydrocele and delayed recurrent varicocele after varicocelectomy in a long-term follow-up. *BJU Int* 2001;87:494-8. [\[CrossRef\]](#)
27. Esposito C, Valla JS, Najmaldin A, Shier F, Mattioli G, Savanelli A, et al. Incidence and management of hydrocele following varicocele surgery in children. *J Urol* 2004;171:1271-3. [\[CrossRef\]](#)
28. Van Batavia JP, Fast AM, Nees SN, Mercado MA, Gaselberti A, Glassberg KI. Incidence, significance and natural history of persistent retrograde venous flow after varicocelectomy in children and adolescents: correlation with catch-up growth. *J Urol* 2013;190:689-95. [\[CrossRef\]](#)
29. Li F, Chiba K, Yamaguchi K, Okada K, Matsushita K, Ando M, et al. Effect of varicocelectomy on testicular volume in children and adolescents: a meta-analysis. *Urology* 2012;79:1340-5. [\[CrossRef\]](#)
30. Salzhauer EW, Sokol A, Glassberg KI. Paternity after adolescent varicocele repair. *Pediatrics* 2004;114:1631-3. [\[CrossRef\]](#)
31. Pajovic B, Radojevic N. Prospective follow up of fertility after adolescent laparoscopic varicocelectomy. *Eur Rev Med Pharmacol Sci* 2013;17:1060-3.
32. Bogaert G, Orye C, De Win G. Pubertal screening and treatment for varicocele do not improve chance of paternity as adult. *J Urol* 2013;189:2298-303. [\[CrossRef\]](#)
33. Çayan S, Şahin S, Akbay E. Paternity rates and time to conception in adolescents with varicocele undergoing microsurgical varicocele repair vs observation only: A single institution experience with 408 patients. *J Urol* 2017;198:195-201. [\[CrossRef\]](#)