



# A Rare Cause of Thrombocytopenia in Infants: Vitamin B12 Deficiency

Mustafa Kömür<sup>1</sup>, İbrahim Bayram<sup>2</sup>, Fatih Erbey<sup>2</sup>, Osman Küçükosmanoğlu<sup>2</sup>

<sup>1</sup>Numune Education and Research Hospital Department of Pediatrics, Adana, Turkey

<sup>2</sup>Çukurova University Faculty of Medicine Departments of Pediatrics, Adana, Turkey.

Eur J Gen Med 2010;7(1):107-110

## ABSTRACT

Thrombocytopenia is the reduction of platelet number to below normal level. It may be due to the decrease in production, increase in destruction, abnormal spreading in the body or the laboratory errors. B12 deficiency is a rarely seen vitamin deficiency in childhood. It presents with megaloblastic anemia and is difficult to diagnose because of various clinical findings. Here we would like to present two cases which were hospitalized to investigate the etiology of anemia and thrombocytopenia. Cases were detected to have vitamin B12 deficiency which is rarely seen in infantile period. A 12-month old male and a 16-month old female admitted with complaints of weakness, bruise and pallor. On physical examination, there was tremor of upper extremities. Anemia, thrombocytopenia and in peripheral blood macrocytes were detected as laboratory findings. B12 vitamins were found to be low. Patients recovered clinically after parenteral vitamin B12 administration. Laboratory findings also changed into normal.

**Key-words:** Anemia, B12 vitamin deficiency, infant, thrombocytopenia.

## INTRODUCTION

Thrombocytopenia is the reduction of platelet number to below normal level. Thrombocytopenia may be due to the decrease in production, increase in destruction, abnormal spreading in the body or the laboratory errors (artifactual, pseudothrombocytopenia). Miscounting might occur if there are giant platelets or due to the aggregation of platelets or if the counting is done from a tube which is poor at amount of anticoagulant. Pseudothrombocytopenia occurs due to the aggregation of platelets when there are anticoagulant addicted platelet agglutinins (1,2).

Increase in platelet destruction is a result of events such as immunological processes (autoimmune (idiopathic thrombocytopenic purpura) and/or alloimmune), non-immunological processes (disseminated intravascular

**Correspondence:** Dr. Mustafa Kömür  
Numune Education and Research Hospital Department of Pediatrics, Adana, Turkey

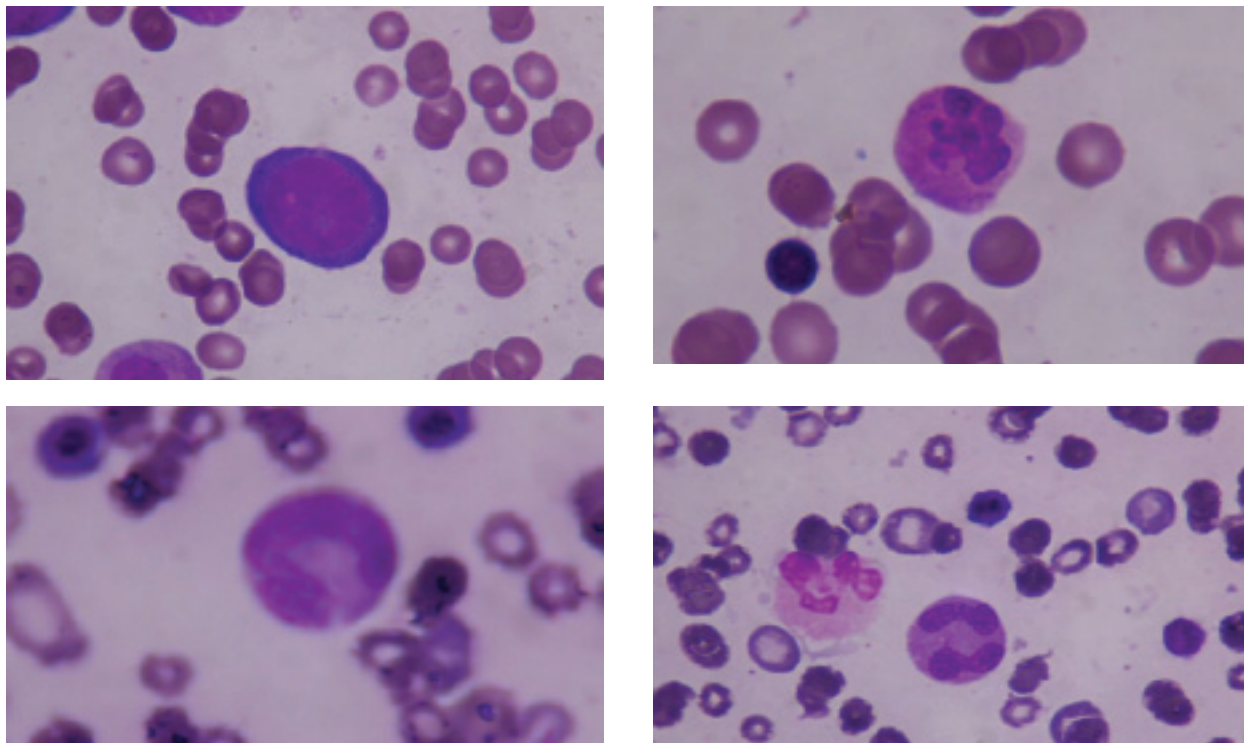


Figure 1-2; Case I, 3-4; Case II: magaloblastic erythroblasts in bone marrow in cases (figure 1 and 3) and hypersegmented neutrophils in peripheral blood smear (figure 2 and 4)

coagulopathy, thrombotic thrombocytopenic purpura, hemolytic-uremic syndrome, prosthetic valves, infections, wounding due to the abnormal vascular surface, cavernous haemangioma) (1,3,4). Decrease in the production of platelet is caused by megakaryocytic hypoplasia, ineffective thrombocytopenia, thrombopoietic malfunction of control and hereditary thrombocytopenia. Thrombocytopenia may also occur due to leukemia, aplastic anemia and bone marrow infiltration of other malign diseases. Shortfall in production can also be seen at TAR Syndrome and Wiskott-Aldrich syndrome. Abnormal distribution or aggregation of platelets can be seen as a result of splenic diseases (neoplastic, congestive, infiltrative and infections), hypothermia and massive transfusions (1). Here, we present 2 infant cases with vitamin B12 deficiency which is a rare cause in thrombocytopenia's etiology at infancy.

#### CASE 1

A 12 month old male applied to our service with complaints of bruise, fatigue, and paleness. In first examination we found that hemoglobin (Hb):7g/dL, hematocrit

(Hct):20.2%, leukocyte (WBC):11.000/mm<sup>3</sup>, platelets (Plt):70.000/mm<sup>3</sup>, mean corpuscular volume (MCV):92.5 fL. In peripheral blood smear red blood cells were macrocytic, neutrophils were hypersegmented (Figure 1). At physical examination, ecchymoses on extremities, paleness of skin and tremor of extremities were detected. The serum Vitamin B12 level checked for anemia and thrombocytopenia was found as 74 pg/mL (normal levels 140-700pg/mL). The serum folate level was at quite normal limits. In bone marrow aspiration megaloblastic changes were recognized (Figure 2). Serum B12 level of his mother was 93pg/mL. One mg parenteral vitamin B12 was injected to the patient for three days. At the end of the third day, we detected reticulocyte response (11.4%). Fast increase of platelets and hematocrit was recorded. And the patient was discharged from the hospital suggesting to get 1 mg vitamin B12 once a week.

#### CASE 2

A 16 month old female admitted with the complaints of bruise, fatigue and paleness. Prior to hospitalization, blood transfusion was carried out at another centre because of the low amount of red blood cells. Laboratory values at the moment of hospitalization were observed

Hb:14.2g/dL, Hct:44.6% (after transfusion), WBC:6.800/mm<sup>3</sup>, plt:26.000/mm<sup>3</sup>, MCV:92.6 fL. Hemotocrit level decreased to 26% during the observation. In peripheral blood smear red blood cells were macrocytic and neutrophils were hypersegmented (Figure 3). At physical examination, there were extensive ecchymotic and petechial lesions and paleness on the skin and tremor of her extremities. Serum B12 level was 81pg/mL (normal level 140-700pg/mL). Serum folate and red blood cell folate levels were normal. Serum B12 level of her mother was 95pg/mL. Megaloblastic changes were detected in bone marrow aspiration (Figure 4). The patient was applied intramuscular 1 mg B12 for 3 days. At the end of the third day, a reticulocyte response (21%) was detected. We saw the fast increase of platelets and hemotocrit. The patient was discharged suggesting to be given 1 mg vitamin B12 once a week.

## DISCUSSION

The deficiency of vitamin B12 that is observed rarely at childhood, and presented with megaloblastic anemia and quite difficult to find out because of various clinical symptoms. Infants B12 deficiency is a rare cause of thrombocytopenia. Vitamin B12 acts as a co-factor during the synthesis phase of the cells in the bone marrow (5).

Hypersegmented neutrophils are seen as an initial finding in peripheral blood when B12 vitamin level is below 100pg/mL. After then, megaloblastic anemia, leukopenia and thrombocytopenia occurs. Furtherly, peripheral neuropathy, paresthesia, loss of sense and mental capacity regression can be observed (6). Vitamin B12 is taken mainly by animal food sources. Unlike the folate it is resistant to boiling. Moreover, unlike the vitamins which are soluble in the water, B12 is stored in the liver, and there is no harmful effects despite excessive intake (5-7).

In infancy, most of vitamin B12 deficiencies occur due to a specific defect of absorption. These defects include natal pernicious anemia (absence of intrinsic factor), juvenile pernicious anemia (autoimmune) and the deficiency in transport of transcobalamin II (8). If the mother is a true vegetarian, due to the inadequate nutrition vitamin B12 deficiency can be observed during the infancy (9). During postnatal period (if the mother is not a true vegetarian or has pernicious anemia) deficiency of B12 is rarely seen at the infants who are fed with maternal milk. B12 storages taken from the mother is usually finished when the baby is 6-9 months old. If the patient is mis-fed or not fed adequately, a clinical condition is seen due to the vitamin B12 deficiency.

Clinically, megaloblastic anemia, leukopenia, thrombocytopenia, peripheral neuropathy, paresthesia, loss of sense, seizure, mental capacity regression, weakness and diarrhea can be seen. Neurological changes can be observed without hematological changes. Upon acceptance of our cases, there existed bruise on the body, paleness, fatigue and tremor of extremities. Increased mean corpuscular volume (MCV) (macrocytic red blood cells), anemia and thrombocytopenia led us think that the patients were suffering from vitamin B12 deficiency (10). When we examined the story of both patients, it is revealed that both infants were fed with only maternal milk (despite 12 and 16 month old). Moreover, because of vitamin B12 deficiency in mothers, the infants also got inadequate B12. Hence, in our cases vitamin B12 deficiency detected to be developed secondarily. Fast response was taken to the B12 support.

In conclusion, one of the seldom causes of thrombocytopenia is vitamin B12 deficiency. Therefore, in the patients with thrombocytopenia who have complaints of petechiae, purpura and abnormal bleeding similar to our cases vitamin B12 deficiency should be considered as an etiological factor. For this reason, we think that if thrombocytopenia is detected in a patient other symptoms of B12 deficiency must be searched out.

REFERENCES

1. Levine SP. Thrombocytopenia: Pathophysiology and classification. In: Greer JP, Foerster J, Lukens JN, Rodgers GM, Paraskevas F, Glader B, Wintrobe's Clinical Hematology, 11th ed. by Lippincott Williams Wilkins, Philadelphia 2004 pp. 1529-1532.
2. Bizzaro N. Platelet satellitosis to polymorphonuclears: cytochemical, immunological, and ultrastructural characterization of eight cases. *Am J Hematol* 1991; 36:235-242.
3. Hope AF, Heyns AD, Lotter MG, et al. Kinetics and sites of sequestration of indium 111-labeled human platelets during cardiopulmonary bypass. *J Thorac Cardiovasc Surg* 1981;81:880-886.
4. Tomer A, Hanson SR, Harker LA. Autologous platelet kinetics in patients with severe thrombocytopenia: discrimination between disorders of production and destruction. *J Lab Clin Med* 1991; 118:546-554.
5. Whitehead VM, Rosenblatt DS, Cooper BA. Megaloblastic Anemias In: Nathan DG, Oski FA, Ginsburg D. Hook AT. *Hematology of Infancy and Childhood* WB Saunders Company 6th ed. Philadelphia 2003; pp.419-455.
6. Carmel R. Megaloblastic Anemias: Disorders of impaired DNA synthesis In: Greer JP, Foerster J, Lukens JN, Rodgers GM, Paraskevas F, Glader B, Wintrobe's Clinical Hematology, 11th ed. by Lippincott Williams Wilkins, Philadelphia 2004 pp.1367-1395.
7. Schwartz E. Megaloblastic Anemias. In: Behrman RE, Kliegman MR, Jenson HB. *Nelson Textbook of Pediatrics* WB Saunders Company 17th ed. Philadelphia 2004 pp. 1611-1613.
8. Ozer EA, Turker M, Bakiler R, Yaprak I, Ozturk C. Involuntary movements in infantile cobalamin deficiency appearing after treatment. *Pediatr Neurol* 2001; 25:81-83.
9. Weiss R, Fogelman Y, Bennett M. Severe vitamin B12 deficiency in an infant associated with maternal deficiency and a strict vegetarian diet. *J Pediatr Hematol Oncol* 2004; 26:270-271.
10. Kalayci O, Çetin M, Kirel B, et al. Neurologic findings of vitamin B12 deficiency: presentation of 7 cases. *Turk J Pediatr* 1996; 38:67-72