

# Choroidal Freckling: It Would be a New Diagnostic Criteria for Type 1 Neurofibromatosis?

Ozer DURSUN<sup>1</sup>, Ozlem TEZOL<sup>2</sup>, Erdem DINC<sup>3</sup>, Mustafa VATANSEVER<sup>1</sup>, Gülhan TEMEL<sup>4</sup>, Pınar DURSUN<sup>5</sup>, Çağlar CITAK<sup>6</sup>

## ABSTRACT

**Purpose:** The aim of this study was to investigate the frequency of choroidal freckling and evaluate the relationship between choroidal freckling (CF) and Lisch nodule in patients with type 1 neurofibromatosis (NF-1).

**Materials-Methods:** The study included 23 pediatric patients with NF-1 and 24 age- and sex-matched healthy controls. Presence of Lisch nodule was detected by biomicroscopic examination and recorded. The presence of CF was investigated by near-infrared reflectance imaging after the pupillary dilation with tropicamide 1%. Diagnostic accuracy of CF was evaluated in patients with NF-1.

**Results:** There was no significant difference in age and gender distributions between the patient and control groups ( $p>0.05$ , for both parameters). The Lisch nodule was detected in 60.8% of patients, while no Lisch nodule was observed in the control group. The CF frequency was found in 82.6% in the patient group whereas in 4.16% in controls. The CF frequency was significantly higher in patients with Lisch nodule compared to patients without ( $p<0.001$ ). The sensitivity and specificity for CF finding were 82.6% and 95.8%, respectively.

**Conclusion:** The present study showed that choroidal abnormalities termed as CF are common in patients with NF-1 and that it would be accepted as a new diagnostic criterion in the following years. However, there is a need for further studies with larger sample size to assess diagnostic accuracy of CF in patients with NF-1.

**Keywords:** Choroidal freckling, Neurofibromatosis, Near-infrared reflectance imaging.

## INTRODUCTION

The neurofibromatosis is a hereditary disease with autosomal dominant inheritance, which causes formation of characteristic lesions in skin, eyes and central and peripheral nervous systems.<sup>1</sup> Based on clinical characteristics and chromosomal defect identified, the neurofibromatosis is classified into 2 groups as type 1 (NF-1) and type 2 (NF-2) neurofibromatosis. The NF-1 occurs as a result of a NF-1 gene defect on chromosome 17. Its frequency has been reported as 1: 2500-3000 births.<sup>2</sup> Today, 7 diagnostic criteria are being used in the diagnosis of NF-1, which were developed by US National Institute of Health in 1988.<sup>3</sup> Presence of two or more criteria is considered as

diagnostic for NF-1. Presence of optic glioma and  $\geq 2$  Lisch nodules are among these criteria. However, many authors have proposed that these criteria should have to be updated.

In recent studies, it was shown that choroidal abnormalities and retinal micro-vascular changes may be present in patients with NF-1.<sup>4,6</sup> In these patients, choroidal abnormalities are observed as bright, patchy, placoid lesions on confocal laser scanning ophthalmoscope, which were termed as choroidal freckling (CF) or choroidal nodule by some authors.<sup>5,7</sup> It is impossible to see these lesion by biomicroscopic examination. Kumar and Singh reported that choroidal findings can be demonstrated by multicolor imaging and optic coherence tomography.<sup>8</sup> It

*This study was presented as a poster in 54th Turkish Pediatric Congress held at Girne, North Cyprus Turkish Republic at 6-9 May 2018.*

1- Assistant Prof. MD., Mersin University Medical School, Ophthalmology Department, Mersin, Turkey

2- Assistant Prof. MD., Mersin University Medical School, Department of Child Health and Diseases, Mersin, Turkey

3- Associate Prof. MD., Mersin University Medical School, Ophthalmology Department, Mersin, Turkey

4- Associate Prof. MD., Mersin University Medical School, Biostatistics Department, Mersin, Turkey

5- Ophthalmologist, Mersin Training and Research Hospital, Dermatology Clinic, Mersin, Turkey

6- Prof. MD., Mersin University Medical School, Department of Child Health and Diseases, Mersin, Turkey

**Received:** 16.10.2019

**Accepted:** 03.01.2020

*Ret-Vit 2020; 29: 140-143*

DOI: 10.37845/ret.vit.2020.29.24

**Correspondence Address:**

Ozer DURSUN

Mersin University Medical School, Ophthalmology Department, Mersin, Turkey

**Phone:**

**E-mail:** drozerdursun@yahoo.com

was suggested that CF frequency is increased by advancing age and that there is a correlation between numbers of Lisch nodules and CF.<sup>9</sup> Moreover, some authors suggested that CF is common in patients with NF-1 and that it would be a diagnostic criterion in subsequent years.<sup>10</sup>

The aim of present study was to investigate the CF frequency and evaluate the relationship between CF and Lisch nodule in patients with NF-1.

## MATERIAL AND METHOD

The study was approved by Ethics Committee on Clinical Research of XXX University. All parents gave written informed consent. The study included 45 eyes of 23 children who were diagnosed as NF-1 at Pediatrics Department of XXX University, Medicine School and consulted to our department between January, 2016 and February, 2018 and 48 eyes of 24 healthy children who had no ocular pathology and presented for refraction examination. Ophthalmologic examination was performed in all NF-1 patients and healthy controls and presence of Lisch nodule was recorded. Then, CF was assessed by near-infrared reflectance imaging using Heidelberg Retina Tomography after the pupillary dilation with tropicamide 1% (Tropamid®, Bilim İlaç, Turkey).

Statistical analyses were performed using MedCalc 17.9.7. Descriptive statistics are presented as mean and standard deviation for continuous parameter whereas count and percent for categorical variables in patient and control groups. Student's t test was used to compare age while Chi-square test was to compare gender distribution between patient and control groups. The Z test was used to assess difference between two rates. In addition, sensitivity and specificity were estimated to assess diagnostic accuracy of CF.

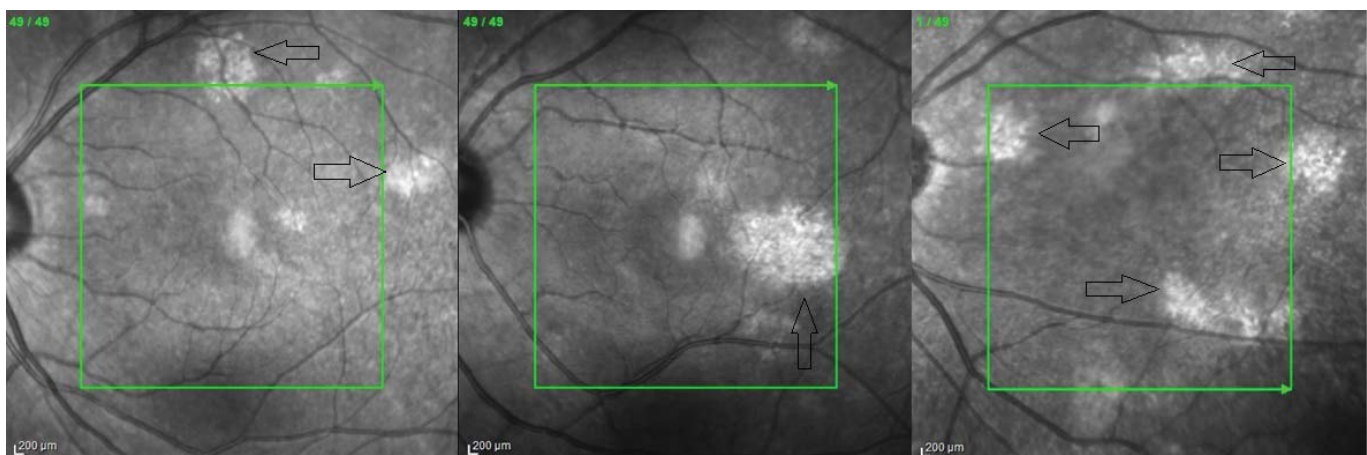
## FINDINGS

Mean age was  $11.35 \pm 4.06$  years in 23 NF-1 patients including 14 boys and 9 girls while  $12.20 \pm 3.61$  years in 24 healthy controls including 11 boys and 13 girls. There was no significant difference in age and gender distributions between patient and control groups ( $p > 0.05$  for both). Of NF-1 patients, Lisch nodule was detected in 60.8% while CF was detected in 82.6% (Picture 1). No Lisch nodule was detected in controls while CF was detected in only one healthy control (4.16%). It was found that CF frequency was significantly higher in patients with Lisch nodule than those without ( $p < 0.001$ ). In patients with or without Lisch nodule, sensitivity and specificity for CF were calculated as 93% and 33%, respectively. When compared to controls, the sensitivity and specificity for CF were 82.6% and 95.8, respectively.

## DISCUSSION

Seven criteria are used in the diagnosis of type 1 neurofibromatosis: 1) six or more café-au-lait spots or hyper pigmented macules greater than 5 mm in diameter in prepubertal children and greater than 15 mm postpubertal; 2) two or more typical neurofibromas or one plexiform neurofibroma; 3) axillary or inguinal freckles; 4) optic nerve glioma; 5) two or more Lisch nodules (iris hamartoma); 6) sphenoid dysplasia or typical long-bone abnormalities such as cortical thinning; 7) first-degree relative with NF1 diagnosed according to above-mentioned criteria.<sup>3</sup>

The Lisch Nodule was first described by Karl Lisch in 1937 and proposed to be associated with NF-1.<sup>11</sup> These nodules are yellow-brown melanocytic hamartomas which probably originate from neural crests and can be localized at anterior surface of iris or anterior chamber angle. This appears as the most striking ocular finding in NF-1 and can be readily detected by biomicroscopic evaluation. Although the Lisch



**Figure 1:** Near-infrared reflectance images in 3 different patients; black arrows show CF areas.

nodules don't cause any ocular morbidity, it is considered as important, since it is one of the diagnostic criteria in NF-1. The presence of Lisch nodules is associated to age and it is unlikely to detect before 2 years of age; however, it can be seen in one-half of patients aged 5 years, in 75% of patients aged 15 years and almost in all patients aged >30 years.<sup>12</sup> In our study, the Lisch nodule frequency was found as 60.8% in agreement with literature. In NF-1, the ocular findings include optic nerve glioma, orbital neurofibromas, café-au-lait spots at eyelids, congenital agenesis of sphenoid duct and congenital glaucoma among other.<sup>7</sup>

The choroidal anomalies in neurofibromatosis were first demonstrated in histopathological studies at 1930s.<sup>13</sup> The lesions observed may correspond to hamartomatous lesions described by Kurusowa.<sup>14</sup> In addition, it has been proposed that these lesions show similar features with Lisch nodule and that they originate from same neural crest in embryologic manner.<sup>15</sup> In recent years, choroidal anomalies could be demonstrated in patients with NF-1 by near-infrared reflectance images without need for histopathological examinations.<sup>4,5,7,17</sup> It has been proposed that an irregular choroidal thickening occurs due to melanocyte proliferation in patients with NF-1 and that near-infrared images can be obtained due to higher content of melanin in these lesions.<sup>15</sup> It isn't possible to detect these choroidal anomalies by fundus examination or fundus fluorescence angiography.<sup>5</sup> In previous studies, these anomalies were classified as dome-like or plaque-like and it was reported that the incidence was higher even in pediatric patients.<sup>7,17</sup> Because of higher melanin content in the lesions, such lesions should have to be distinguished from ocular melanosis. As similar to patients with NF-1, patchy hyper-reflectance images can be seen in patients with ocular melanosis on near-infrared reflectance imaging.

Recent studies showed that these lesions are also increased by advancing age as similar to Lisch nodule and that they are localized at posterior pole in particular.<sup>16</sup> In several studies, it was shown that the frequency of these anomalies varied 60.5% and 100% in NF-1 patients aged <16 years.<sup>4,5,7,10,18</sup> In a study by Viola et al., CF was detected in 82% of patients while it was reported as 7% in healthy controls.<sup>5</sup> Again, in the same study, the sensitivity and specificity of CF were estimated as 83% and 96%, respectively. In our study, CF was detected in 83% of patients whereas in 4.16% of healthy controls in agreement with study by Viola et al. In addition, in our study, the sensitivity and specificity of CF were calculated as 82.6% and 95.8%, respectively. However, it was seen that sensitivity was increased but specificity was decreased when presence of CF was assessed in patients with or without Lisch nodule. In addition, it was proposed that, besides CF, the choroid

thickness might be decreased in these patients, which can be associated to choroidal blood flow.<sup>17</sup>

In conclusion, both our study and those in the literature show that choroidal anomalies, termed as CF, are very common in patients with NF-1 and they would be accepted as a novel diagnostic criteria in the future. It seems that use of near-infrared reflectance images provides rapid and objective outcomes without need for an invasive intervention in detection of these anomalies and may provide a significant advantage to clinicians in diagnosis. However, further population-based studies are needed to add these anomalies into diagnostic criteria.

## REFERENCES

- 1- Moramarco A, Giustini S, Nofroni I, et al. Near-infrared imaging: an in vivo, non-invasive diagnostic tool in neurofibromatosis type 1. *Graefes Arch Clin Exp Ophthalmol* 2018;256:307-11.
- 2- Friedman JM, Gutmann DH, MacCollin M, et al. Neurofibromatosis: phenotype, natural history, and pathogenesis. In: Friedman JM, Gutmann DH, MacCollin M, and Riccardi VM eds. (3th Ed) Johns Hopkins University Press, Baltimore, 1999:380.
- 3- Tadani G, Milani D, Menni F, et al. Is it time to change the neurofibromatosis type 1 diagnostic criteria?. *Eur J Intern Med* 2014;25:506-10.
- 4- Yasunari T, Shiraki K, Hattori H, et al. Frequency of choroidal abnormalities in neurofibromatosis type 1. *Lancet* 2000;356:988-92.
- 5- Viola F, Villani E, Natacci F, et al. Choroidal abnormalities detected by near-infrared reflectance imaging as a new diagnostic criterion for neurofibromatosis 1. *Ophthalmology* 2012;119:369-75.
- 6- Muci-Mendoza R, Ramella M, Fuenmayor R. Corkscrew retinal vessels in neurofibromatosis type 1: report of 12 cases. *Br J Ophthalmol* 2002;86:282-4.
- 7- Vagge A, Nelson BL, Capris P, et al. Choroidal freckling in pediatric patients affected by neurofibromatosis type 1. *J Pediatr Ophthalmol Strabismus* 2016;53:271-4.
- 8- Kumar V, Singh S. Multimodal imaging of choroidal nodules in neurofibromatosis type-1. *Indian J Ophthalmol* 2018;66:586-8.
- 9- Makino S, Tampo H, Arai Y, et al. Correlations between choroidal abnormalities, Lish nodules and age in patients with neurofibromatosis type 1. *Clin Ophthalmol* 2014;8:165-8.
- 10- Göktaş S, Sakarya Y, Özçimen M, et al. Frequency of choroidal abnormalities in pediatric patients with neurofibromatosis type 1. *J Pediatr Ophthalmol Strabismus* 2014;51:204-8.
- 11- Lubs ML, Bauer MS, Formas ME, et al. Lisch nodules in neurofibromatosis type 1. *N Engl J Med* 1991;324:1264-6.

- 12- Helfferich J, Nijmeijer R, Brouwer OF, et al. Neurofibromatosis type 1 associated low grade gliomas: a comparison with sporadic low grade gliomas. *Crit Rev Oncol Hematol* 2016;104:30–41.
- 13- Kurosawa A, Kurosawa H. Ovoid bodies in choroidal neurofibromatosis. *Arch Ophthalmol* 1982;100:1939-41.
- 14- Wallace MR. Neurofibromatosis: phenotype, natural history, and pathogenesis. *Am J Hum Genet* 2000;67:264.
- 15- Karaconji T, Whist E, Jamieson RV, et al. Neurofibromatosis type 1: review and update on emerging therapies. *Asia Pac J Ophthalmol* 2019;8:62-72.
- 16- Nakakura S, Shiraki K, Yasunari T, et al. Quantification and anatomic distribution of choroidal abnormalities in patients with type I neurofibromatosis. *Graefes Arch Clin Exp Ophthalmol* 2005;243:980-4.
- 17- Abdolrahimzadeh S, Felli L, Plateroti R, et al. Morphologic and vasculature features of the choroid and associated choroid-retinal thickness alterations in neurofibromatosis type 1. *Br J Ophthalmol* 2015;99:789–93.
- 18- Parrozzani R, Clementi M, Frizziero L, et al. In vivo detection of choroidal abnormalities related to NF1: feasibility and comparison with standart NIH diagnostic criteria in pediatric patients. *Invest Ophthalmol Vis Sci* 2015;56:6036-42.

Copyright of Retina-Vitreus/Journal of Retina-Vitreous is the property of Retina-Vitreus and its content may not be copied or emailed to multiple sites or posted to a listserv without the copyright holder's express written permission. However, users may print, download, or email articles for individual use.