



## Original Article

## Short-cut diagnostic tool in cystinosis: Bone marrow aspiration

Serra Sürmeli Döven,<sup>1</sup> Ali Delibaş,<sup>1</sup> Uğur Raşit Kayacan<sup>2</sup> and Selma Ünal<sup>3</sup>Departments of <sup>1</sup>Pediatric Nephrology, <sup>2</sup>Pediatrics, and <sup>3</sup>Pediatric Hematology, Mersin University Faculty of Medicine, Mersin, Turkey

**Abstract** **Background:** Cystinosis is a rare metabolic genetic disorder caused by a mutation in *cystinosin lysosomal cystine transporter (CTNS)*. The diagnosis of nephropathic cystinosis (NC) is made by observing corneal cystine crystals and/or measuring the cystine content of leukocytes. *CTNS* mutation analysis confirms the diagnosis of cystinosis, but leukocyte cystine measurement and *CTNS* analysis have not been widely available, and cystine crystals in the cornea may not be apparent in the first months of life. Cystine crystal deposition can be seen in the bone marrow earlier than corneal deposition, in patients with NC.

**Methods:** Ten patients with cystinosis diagnosis were enrolled in the study. Medical records were reviewed retrospectively to collect demographic and clinical data such as age at diagnosis, disease presentation, parental consanguinity, family history, corneal cystine deposition, leukocyte cystine level, bone marrow cystine deposition, presence of renal failure, follow-up time and prognosis.

**Results:** Cystine crystals were seen in all of the patients' fresh bone marrow aspiration samples. Eight patients had corneal cystine deposition. Leukocyte cystine measurement could have been performed in four patients who had come from another center. Complications such as pulmonary hypertension and idiopathic intracranial hypertension (IIH) were observed in two patients.

**Conclusions:** Bone marrow aspiration might be an easy and short-cut diagnostic tool for NC especially when it is not possible to measure fibroblast cystine content. Additionally some rare complications such as pulmonary hypertension and IIH can be encountered during the course of NC.

**Key words** bone marrow aspiration, childhood, cystinosis, idiopathic intracranial hypertension, pulmonary hypertension.

Cystinosis is a rare autosomal-recessive lysosomal storage disease with an incidence of 0.5–1.0 per 100 000 live births. Three clinical forms with somewhat overlapping phenotypes are recognized. The most severe and frequent form, affecting 95% of patients, is termed infantile nephropathic cystinosis (NC) (OMIM 219800); patients generally develop clinical symptoms related to renal Fanconi syndrome during the first year of life. Juvenile or late-onset NC (OMIM 219900) is usually diagnosed later in childhood or during adolescence. In this phenotype, patients present with milder forms of renal Fanconi syndrome or with isolated proteinuria. Finally the ocular or adult form (OMIM 219750) is characterized by isolated symptoms related to corneal cystine crystal deposition and is rarely diagnosed before adulthood.<sup>1,2</sup>

The diagnosis can be made by measuring cystine in white blood cells (WBC), which will be above the upper limit of the normal for carriers of a *cystinosin lysosomal cystine transporter (CTNS)* mutation (>1 nmol cystine/mg protein). *CTNS* analysis confirms the diagnosis of cystinosis. Corneal cystine

crystals can be seen by an experienced ophthalmologist in most children aged >12 months and are always present in patients aged >18 months.<sup>3</sup> In recent decades, NC prognosis has considerably improved due to the introduction of treatment with 2-mercaptoethylamine, or cysteamine, which allows cystine clearance from the lysosomal compartment.<sup>2,4–6</sup> Cysteamine treatment has considerably improved renal survival, as well as symptoms related to cystine accumulation in other organs,<sup>7–10</sup> therefore early diagnosis and treatment are important for long-term prognosis. As a limitation, however, leukocyte cystine measurement and *CTNS* mutation analysis are not readily available in most laboratories. In this study, we review and report on the clinical features of 10 patients with NC initially diagnosed by bone marrow aspiration at the present clinic.

## Methods

Ten patients (seven boys, three girls) with NC who were followed at the present institution from 2004 to 2016 were enrolled in the study. In all patients the diagnosis was made on detection of cystine crystals in bone marrow aspiration upon clinical and laboratory suspicion of NC. We performed bone marrow aspiration from the posterior superior iliac spine in patients >12 months of age, and from the anterior tibia for

Correspondence: Serra Sürmeli Döven, MD, Department of Pediatric Nephrology, Mersin University Faculty of Medicine, Çiftlikköy-Yenişehir, Mersin, Turkey. Email: serrasurmel@yahoo.com

Received 20 April 2016; revised 13 January 2017; accepted 7 August 2017.

patients <12 months of age. Ketamine was used for premedication. Without stain, fresh bone marrow aspirates were evaluated for cystine crystals under light microscopy in a few minutes after aspiration. Medical records were reviewed retrospectively to collect demographic and clinical data such as age at diagnosis, disease presentation, parental consanguinity, family history, corneal cystine deposition, leukocyte cystine level, bone marrow cystine deposition, presence of renal failure, follow-up time and prognosis. Pulmonary hypertension was diagnosed on mean pulmonary artery pressure >25 mmHg at rest. Idiopathic intracranial hypertension (IIH) was diagnosed on cerebrospinal fluid (CSF) opening pressure >200 mmH<sub>2</sub>O on lumbar puncture with normal cranial magnetic resonance imaging (MRI).

## Results

Median age at diagnosis was 32.7 months (range, 3–96 months; Table 1). Nine had parental consanguinity and positive family history for NC. Eight patients had corneal cystine deposition. Leukocyte cystine measurement could have been performed in four patients who had come from another center, given that the test was not available at the present center. Bone marrow aspiration was performed in all patients and under light microscopy, colorless, hexagonal cystine crystals of varying size were seen in all fresh bone marrow aspiration samples (Fig. 1). We did not observe a correlation between the amount of cystine deposits in bone marrow and age or disease severity. Median follow-up time was 48.5 months (range, 6–132 months). Three patients had renal failure. Median age at renal failure was 70 months (range, 29–96 months). Cysteamine was given to all patients when cystinosis diagnosis was made. Cysteamine eye drops were initiated in the patients who had corneal cystine deposition. Other treatments received were thyroxine, indomethacin, potassium citrate, calcitriol, sodium hydrogen carbonate and phosphate with Joule's solution. In the patients who developed chronic renal failure (patients 3–5) compliance with therapy was poor. Patient 5 had diplopia and papilledema during follow up at 69 months of age. CSF opening pressure was >200 mmH<sub>2</sub>O with normal CSF biochemistry. Cranial MRI and venography were normal. Thus this patient was diagnosed with IIH. He died due to severe acidosis, chronic renal failure and cardiac arrhythmia. Patient 3 died of cardiac and hepatic failure. Patient 4 had been followed up in other center for Fanconi syndrome at 2–7 years of age. He was admitted to the present hospital at 8 years of age, with chronic kidney failure. Cystinosis diagnosis was made on corneal cystine deposition and bone marrow aspiration, and cysteamine was initiated at the same time. He was diagnosed with dilated cardiomyopathy at 10 years of age and received digoxin, diuretics and carnitine therapy. At the age of 15 he was admitted to hospital with coughing and respiratory distress. On echocardiography, pulmonary artery wedge pressure was 85 mmHg. He was diagnosed with pulmonary hypertension and started on bosentan. One year after initiation of

bosentan, symptoms completely disappeared and pulmonary artery wedge pressure decreased on echocardiography.

## Discussion

Here we present the cases of 10 patients with NC who were diagnosed on cystine deposition in bone marrow aspiration. There are only 12 reported cases of bone marrow involvement in NC.<sup>11–22</sup> NC diagnosis is made on the observation of corneal cystine crystals and/or measurement of the cystine content of leukocytes,<sup>2</sup> but typical crystals in the bone marrow are diagnostic.<sup>22</sup> The diagnosis can be confirmed on genetic analysis, but leukocyte cystine measurement and, *CTNS* analysis are not widely available. Early diagnosis and treatment can delay kidney function impairment and other complications secondary to deposition of cystine crystals in various tissues.<sup>22</sup> In the present case series, typical hexagonal cystine crystals were observed on bone marrow aspirate smear in all patients, and cysteamine therapy initiated. Leukocyte cystine could have been performed in only four patients from another center. Based on our experience in NC patients, we consider that bone marrow aspiration is a reasonably easy, useful and early diagnostic method, especially in the settings where leukocyte cystine measurement is not possible.

In the literature, the youngest patient to have cystine crystals on bone marrow aspiration was 4 months of age.<sup>15</sup> In the present series we detected cystine crystals in the bone marrow aspirate of a 3-month-old patient. No study in the literature has carried out simultaneous leukocyte cystine measurement and bone marrow aspiration for NC diagnosis, therefore we have no information on the time of cystine crystal accumulation in the bone marrow. We think, however, that it occurs earlier than cystine deposition in the eye, given the presence of cystine crystals in two patients' bone marrow aspirate smears (patients 9,10) and lack of corneal cystine deposition. Cystine crystals in the cornea may not appear in the first months of life, but are always present by 18 months of age.<sup>2</sup>

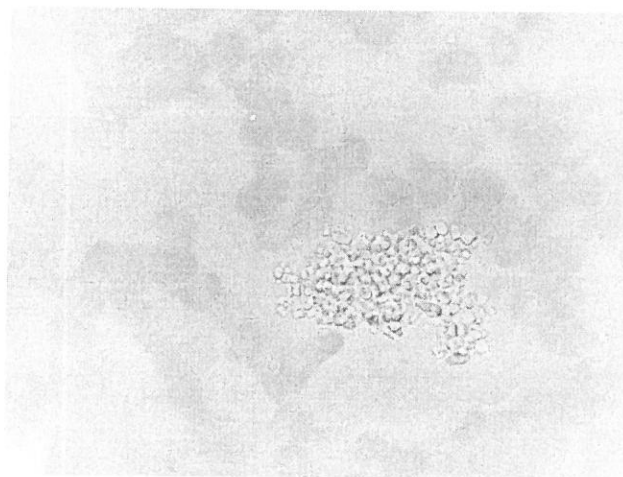
Abdulsalam *et al.* reported on a 4-year-old boy with pallor, visual problems and recurrent multiple bilateral renal stones and pancytopenia. Bone marrow aspiration showed numerous clear cystine crystals, apparently free and within macrophages, and cystinosis diagnosis was made.<sup>16</sup> In a 1-year-old boy presenting with growth failure, polyuria and polydipsia, bone marrow aspiration indicated increased numbers of macrophages containing polygonal crystals.<sup>22</sup> Cystinosis diagnosis was made on these findings and on the observation of corneal cystine crystals. We observed hexagonal free cystine crystals of varying size in fresh bone marrow aspiration samples for in all patients. We did not use stain for aspirates, and evaluated them in a few minutes immediately after bone marrow aspiration because cystine crystals can dissolve rapidly.

Bone marrow aspiration is more invasive compared with leukocyte cystine measurement or observation of corneal cystine deposition. When it is not possible to perform leukocyte cystine measurement or the child is younger than 12 months of age (given that corneal cystine deposition was

**Table 1** Clinical and laboratory features

Patient ID no.	Age at diagnosis (months)/gender	Presentation	Parental consanguinity	Family history	Corneal cystine deposition	Leukocyte cystine (nmol/mg protein)	Bone marrow cystine deposition	Renal failure/Age at renal failure (months)	Follow up (months)
1	87/F	Corneal cystine deposition	(-)	(-)	(+)	1.45	(+)	(-)	16
2	14/F	Polyuria, polydipsia	(+)	(+)	(+)	-	(+)	(-)	29
3	49/M	Polyuria, polydipsia, vomiting, sibling history	(+)	(+) Sibling of patient 4	(+)	-	(+)	(+)/70	124 DOD
4	96/M	Polyuria, polydipsia	(+)	(+) Sibling of patient 3	(+)	-	(+)	(+)/96	132
5	16/M	Polyuria, polydipsia	(+)	(+) Sibling of patient 6	(+)	3.8	(+)	(+)/29	70 DOD
6	16/M	Sibling history	(+)	(+) Sibling of patient 5	(+)	1.5	(+)	(-)	35
7	3/F	Vomiting, diarrhea	(+)	(-)	(+)	-	(+)	(-)	67
8	13/M	Polyuria, polydipsia	(+)	(+) Three siblings DOD	(+)	-	(+)	(-)	52
9	23/M	Polyuria, polydipsia	(+)	(+)	(-)	-	(+)	(-)	45
10	10/M	Polyuria, polydipsia	(+)	(+)	(-)	2.76	(+)	(-)	6

DOD, died of disease.

**Fig. 1** Cystine crystals in bone marrow (patient 10).

seen in children older than 12 months), we suggest bone marrow aspiration as a diagnostic tool for cystinosis.

Through cystine deposition, NC affects various organs. Myocardial cystine deposition has been reported in the literature.<sup>23–25</sup> There is also a report of cardiomyopathy caused by cystinosis and dissecting aortic aneurysm in a 7-year-old boy.<sup>26</sup> There are four NC case reports associated with coronary artery dilatation.<sup>27</sup> The myocardium and vessels can be affected by long-standing hypertension, uremia, altered calcium-phosphorus metabolism due to renal osteodystrophy, large arteriovenous fistulae, renal transplantation, drugs and infection,<sup>25</sup> but the association between NC and coronary artery dilatation has not been clarified as yet. Patient 4 had pulmonary hypertension during follow up. He was diagnosed with dilated cardiomyopathy at 10 years of age, and received digoxin, diuretics and carnitine. At the age of 15 he was admitted to hospital because of coughing and respiratory distress. Clinical examination indicated crackling rales at the base of the right lung, I/VI degree systolic murmur and hepatosplenomegaly. There were no finding of congestion or infiltration on chest X-ray. Echocardiography indicated pulmonary artery wedge pressure 85 mmHg. He was diagnosed with pulmonary hypertension and started on bosentan. One year after initiation of bosentan, the symptoms had completely disappeared. Pulmonary artery wedge pressure was 80 mmHg on echocardiography. To our knowledge this is the first case of NC associated with pulmonary hypertension and which improved with bosentan. We think that cardiomyopathy might have developed secondary to cystine deposition in myocardial cells, and that this may have been the underlying reason for development of pulmonary hypertension in the long term.

Although there is evidence of central nervous system dysfunction late in the course of cystinosis,<sup>28–33</sup> cerebral involvement is not a common feature of the disease.<sup>34</sup> So far eight cases of IIH associated with cystinosis have been reported.<sup>34</sup> IIH, also known as pseudotumor cerebri or benign intracranial hypertension, is the diagnostic term used for the syndrome

defined by the modified Dandy criteria.<sup>35</sup> Whereas headache is the most common symptom of IIH, transient visual obscurations, pulsatile intracranial noises, and diplopia also can be present.<sup>36</sup> Papilledema can be seen with IIH. In the present series we also encountered this relatively rare complication of cystinosis. Patient 5 developed diplopia during follow up. He had received levothyroxine, potassium citrate, potassium carbonate, calcitriol, magnesium hydroxide, cysteamine, calcium diacetate and Shohl's solution. His serum creatinine was 4 mg/dL. Neurological examination was normal except for papilledema. Cranial MRI and venography were normal. CSF opening pressure was >200 mmH<sub>2</sub>O with normal CSF composition, therefore he was diagnosed with IIH. After treatment with furosemide and repeated lumbar punctures, papilledema resolved. The patient died, however, due to severe acidosis, chronic renal failure and cardiac arrhythmia. Several reports have suggested that prednisone, growth hormone, cyclosporine, oral contraceptives, vitamin D, and levothyroxine are risk factors for IIH.<sup>37–43</sup> Certain complications of cystinosis, such as renal glomerular damage, could predispose to IIH.<sup>44,45</sup> Blockage of CSF resorption at the level of the arachnoid villi may represent the cause of IIH in cystinosis patients.<sup>34</sup> Post-mortem observations have led to the conclusion that hydrocephalus results from abnormal secretion of CSF by an infiltrated choroid plexus.<sup>28</sup> We think the present patient developed IIH due to drug treatment (levothyroxine, vitamin D). Also, the renal failure could have contributed to the development of IIH. We could not perform postmortem examination, but cystine accumulation in the choroid plexus might also have led to blockage of CSF resorption. This rare complication must be kept in mind when diplopia and papilledema develop in a patient with NC.

In conclusion, bone marrow aspiration is a simple and cheap method for the early diagnosis of NC, especially in clinical settings where more sophisticated genetic tests are unavailable. Additionally, some rare complications such as IIH and pulmonary hypertension may be seen in patients with NC in the long term, with specific symptoms.

## Disclosure

The authors declare no conflict of interest.

## Author contributions

S.S.D. and A.D. designed the study, S.S.D. wrote the study, U.R.K. and S.Ü. collected and analyzed data. All authors read and approved the final manuscript.

## References

- 1 Yung L, Xiaohui Z, Chaitali S. Pancytopenia in a patient with cystinosis secondary to myelosuppression from cystine crystal deposition: A case report. *J. Med. Case Rep.* 2015; **9**: 205.
- 2 Gahl WA, Thoene JG, Schneider JA. Cystinosis. *N. Engl. J. Med.* 2002; **347**: 111–21.
- 3 Emma F, Nesterova G, Langman C *et al.* Nephropathic cystinosis: An international consensus document. *Nephrol. Dial. Transplant.* 2014; **29** (Suppl. 4): iv87–94.
- 4 Pisoni RL, Thoene JG, Christensen HN. Detection and characterization of carrier-mediated cationic amino acid transportin lysosomes of normal and cystinotic human fibroblasts. Role in therapeutic cystine removal? *J. Biol. Chem.* 1985; **260**: 4791–8.
- 5 Schneider JA, Clark KF, Greene AA *et al.* Recent advances in the treatment of cystinosis. *J. Inher. Metab. Dis.* 1995; **18**: 387–97.
- 6 Gahl WA, Reed GF, Thoene JG *et al.* Cysteamine therapy for children with nephropathic cystinosis. *N. Engl. J. Med.* 1987; **316**: 971–7.
- 7 Theodoropoulos DS, Krasnewich D, Kaiser-Kupfer MI, Gahl WA. Classic nephropathic cystinosis as an adult disease. *JAMA* 1993; **270**: 2200–4.
- 8 Gahl WA, Balog JZ, Kleta R. Nephropathic cystinosis in adults: Natural history and effects of oral cysteamine therapy. *Ann. Intern. Med.* 2007; **147**: 242–50.
- 9 Markello TC, Isa B, Gahl WA. Improved renal function in children with cystinosis treated with cysteamine. *N. Engl. J. Med.* 1993; **328**: 1157–62.
- 10 Kimonis VE, Troendle J, Rose SR, Yang M, Markello T, Gahl W. Effects of early cysteamine therapy on thyroid function and growth in nephropathic cystinosis. *J. Clin. Endocrinol. Metab.* 1995; **80**: 3257–61.
- 11 Busuttill DP, Liu Yin JA. The bone marrow in hereditary cystinosis. *Br. J. Haematol.* 2000; **111**: 385.
- 12 Gebrail F, Knapp M, Perotta G, Cuaing H. Crystalline histiocytosis in hereditary cystinosis. *Arch. Pathol. Lab. Med.* 2002; **126**: 1135.
- 13 Quinn JP, Royston D, Murphy PT. Bone marrow findings in hereditary cystinosis with renal failure. *Am. J. Hematol.* 2004; **76**: 79.
- 14 Bigley V, Bhartia S, Wood A. Nephropathic cystinosis with bone marrow involvement. *Br. J. Haematol.* 2007; **136**: 180.
- 15 Emadi A, Burns KH, Confer B, Borowitz MJ, Streiff MB. Hematological manifestations of nephropathic cystinosis. *Acta Haematol.* 2008; **119**: 169–72.
- 16 Abdulsalam AH, Khamis MH, Bain BJ. Diagnosis of cystinosis from a bone marrow aspirate. *Am. J. Hematol.* 2013; **88**: 151.
- 17 Demirsoy U, Ekinici Z. Early bone marrow failure in a 6-year-old with cystinosis. *Pediatr. Hematol. Oncol.* 2015; **32**: 212–4.
- 18 Kara B, Alpay H, Nayır A, Devicioğlu Ö, Emre S, Şirin A. [A case of cystinosis]. *Türk. Pediatr. Ars.* 2014; **27**: 3 (in Turkish).
- 19 Monier L, Mauvieux L. Cystine crystals in bone marrow aspirate. *Blood* 2015; **126**: 1515.
- 20 Yarah N, Bay A, Işık P *et al.* The bone marrow in hereditary cystinosis. *Türk. J. Hematol.* 2008; **25**: 110.
- 21 Vicari P, Stel VM. Cystine crystals in bone marrow. *N. Engl. J. Med.* 2015; **373**: e27.
- 22 Ansari S, Aliabad GM, Saeed Y. Cystinosis: Diagnostic role of bone marrow examination. *Türk. J. Haematol.* 2014; **31**: 106.
- 23 Gahl WA, Dalakas MC, Charnas L *et al.* Myopathy and cystine storage in muscles in a patient with nephropathic cystinosis. *N. Engl. J. Med.* 1988; **319**: 1461–4.
- 24 Kir'ianov NA, Bazhenov EL, Stetsenko EV. [Cystinosis in an adult]. *Ark. Patol.* 1992; **54**: 34–6 (in Russian).
- 25 Dixit MP, Greifer I. Nephropathic cystinosis associated with cardiomyopathy: A 27-year clinical follow-up. *BMC Nephrol.* 2002; **3**: 8–11.
- 26 Strayer DS. Cystinosis and dissecting aortic aneurysm in a 7-year-old boy. *Am. J. Dis. Child.* 1979; **133**: 436–8.



- 27 Olgar S, Nisli K, Dindar A *et al.* Can cystinosis cause coronary artery dilatation? *Pediatr. Cardiol.* 2006; **27**: 263–8.
- 28 Ross DL, Strife CF, Towbin R, Bove KE. Nonabsorptive hydrocephalus associated with nephropathic cystinosis. *Neurology* 1982; **32**: 1330–4.
- 29 Jonas AJ, Conley SB, Marshall R, Johnson RA, Marks M, Rosenberg H. Nephropathic cystinosis with central nervous system involvement. *Am. J. Med.* 1987; **83**: 966–70.
- 30 Fink JK, Brouwers P, Barton N *et al.* Neurologic complications in long-standing nephropathic cystinosis. *Arch. Neurol.* 1989; **46**: 543–8.
- 31 Nichols SL, Press GA, Schneider JA, Trauner DA. Cortical atrophy and cognitive performance in infantile nephropathic cystinosis. *Pediatr. Neurol.* 1990; **6**: 379–81.
- 32 Vogel DG, Malekzadeh MH, Cornford ME, Schneider JA, Shields WD, Vinters HV. Central nervous system involvement in nephropathic cystinosis. *J. Neuropathol. Exp. Neurol.* 1990; **49**: 591–9.
- 33 Broyer M, Tete MJ, Guest G, Bertheleme JP, Labrousse F, Poisson M. Clinical polymorphisms of cystinosis encephalopathy: Results of treatment with cysteamine. *J. Inherit. Metab. Dis.* 1996; **19**: 65–75.
- 34 Dogulu C, Tsilou E, Rubin B *et al.* Idiopathic intracranial hypertension in cystinosis. *J. Pediatr.* 2004; **145**: 673–8.
- 35 Smith JL. Whence pseudotumor cerebri? *J. Clin. Neuroophthalmol.* 1985; **5**: 55–6.
- 36 Wall M, George D. Idiopathic intracranial hypertension: A prospective study of 50 patients. *Brain* 1991; **114**: 155–80.
- 37 Cruz OA, Fogg SG, Roper-Hall G. Pseudotumor cerebri associated with cyclosporine use. *Am. J. Ophthalmol.* 1996; **122**: 436–7.
- 38 Bulens C, De Vries WA, van Crevel H. Benign intracranial hypertension: A retrospective and follow-up study. *J. Neurol. Sci.* 1979; **40**: 147–57.
- 39 Rogers AH, Rogers GL, Bremer DL, McGregor ML. Pseudotumor cerebri in children receiving recombinant human growth hormone. *Ophthalmology* 1999; **106**: 1186–9.
- 40 Walker A, Adamkiewicz J. Pseudotumor cerebri associated with prolonged corticosteroid therapy: Report of four cases. *JAMA* 1964; **188**: 779–84.
- 41 Amrani Y, Terriza F, Moreno C, Casado A. Pseudotumor cerebri caused by vitamin excess due to intake of milk enriched with A and D vitamins. *Rev. Neurol.* 1996; **24**: 1304–5.
- 42 Raghavan S, DiMartino-Nardi J, Saenger P, Linder B. Pseudotumor cerebri in an infant after L-thyroxine therapy for transient neonatal hypothyroidism. *J. Pediatr.* 1997; **130**: 478–80.
- 43 Wall M. Idiopathic intracranial hypertension. *Neurol. Clin.* 1991; **9**: 73–95.
- 44 Chang D, Nagamoto G, Smith WE. Benign intracranial hypertension and chronic renal failure. *Cleve. Clin. J. Med.* 1992; **59**: 419–22.
- 45 Obeid T, Awada A, Huraib S, Quadri K, Abu-Romeh S. Pseudotumor cerebri in renal transplant recipients: A diagnostic challenge. *J. Nephrol.* 1997; **10**: 258–60.