

# CUTANEOUS MASTOCYTOSIS WITH SIGNIFICANT LANGERHANS CELL INFILTRATION. A CASE REPORT

<https://doi.org/10.26574/rojced.2018.5.1.32>

Begüm Ünlü<sup>1</sup>, İclal Gürses<sup>2</sup>, Ümit Türsen<sup>1</sup>

<sup>1</sup>Department of Dermatology, Mersin University School of Medicine, Mersin, Turkey  
<sup>2</sup>Department of Pathology, Mersin University School of Medicine, Mersin, Turkey

Corresponding author:

Begüm Ünlü  
Mersin University Hospital Çiftlikköy/ Yenişehir/ Mersin  
Tel.: +90 05314267635  
E-mail: begumunlu@mersin.edu.tr

**Open Access Article**

## Abstract

### Keywords:

mastocytosis,  
Langerhans,  
Darier's sign.

### Cite this article:

Begüm Ünlü, İclal Gürses, Ümit Türsen.  
Cutaneous mastocytosis with significant Langerhans cell infiltration. A case report. *RojCED* 2018;5(1):32-35.  
<https://doi.org/10.26574/rojced.2018.5.1.32>

Mastocytosis and Langerhans cell histiocytosis are rare diseases, developing from the proliferation of bone marrow cells. Although both diseases may present with various lesions, reddish brown papules are a common manifestation. Darier's sign, which shows activation of mast cells, may help for differential diagnosis. There are only four cases showing prominent Langerhans and mast cells infiltration in the same lesion in the literature. In these cases, because of Darier's sign positivity, dermatologic examination proposes the diagnosis of mastocytosis. We present a nine-month-old female patient admitted to our dermatology department with reddish brown papules, which are evident in the trunk and neck since birth and urticating upon stroking. In the patient's history and physical examination, there are no other signs or symptoms of systemic involvement. The coexistence of Langerhans and mast cells has been demonstrated by immunohistochemical stainings.

<https://doi.org/10.26574/rojced.2018.5.1.32>

### Introduction

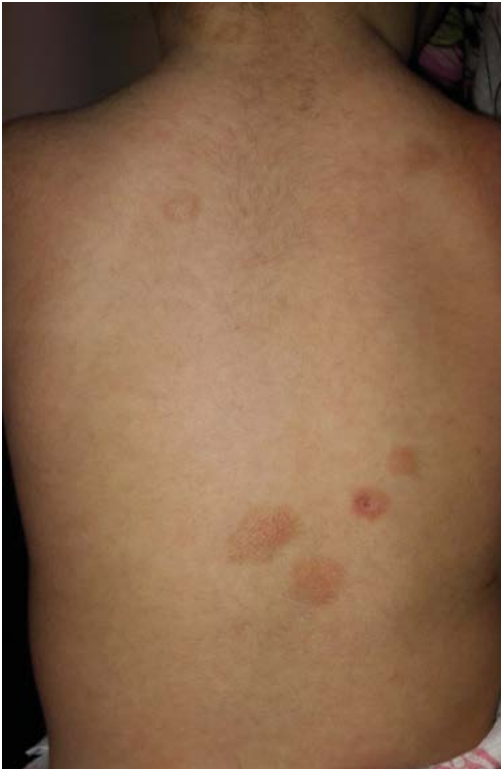Mastocytosis and Langerhans cell histiocytosis (LCH) are both proliferative diseases, which are derived from bone marrow cells. Both diseases may cause cutaneous lesions and systemic involvement. Also, they may have a similar clinical presentation such as brownish papules and plaques. The Darier's sign, a characteristic feature of mastocytosis, can be a clue for the differential diagnosis of these diseases. Only four cases characterized by prominent mast and Langerhans cell infiltration in the same biopsy specimen have been reported in the literature (1-4).

### Case report

A nine-month-old female patient was admitted to our dermatology clinic with rash. Her family noticed the multiple lesions soon after birth.

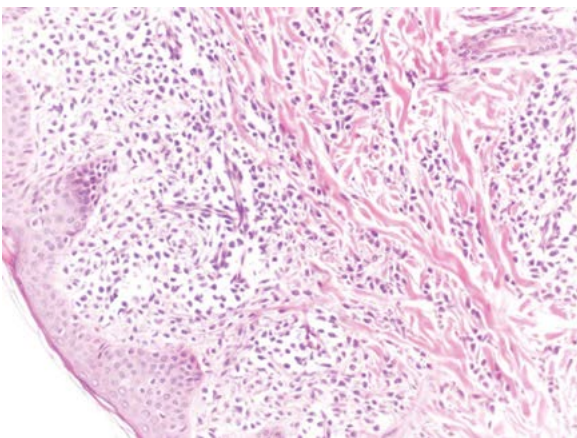
The lesions were several red brown slightly raised papules and plaques on the chest, abdomen, back, neck and left leg (Figure 1). The widest plaque was approximately 20 mm in diameter. Urtication upon stroking was demonstrated on her lesions and accepted as a positive Darier's sign. The patient was otherwise in good health. She was born by caesarean section at term from uncomplicated pregnancy. The parents had first cousin consanguinity. In the family history there was no recall of a disease, except for the goiter of her mother. She had normal psycho-motor development. The weight and height were within the normal percentiles according to national growth charts. Her physical examination was normal, except for the cutaneous findings.

The lab results were within normal limits. No evidence of eosinophilia was seen.



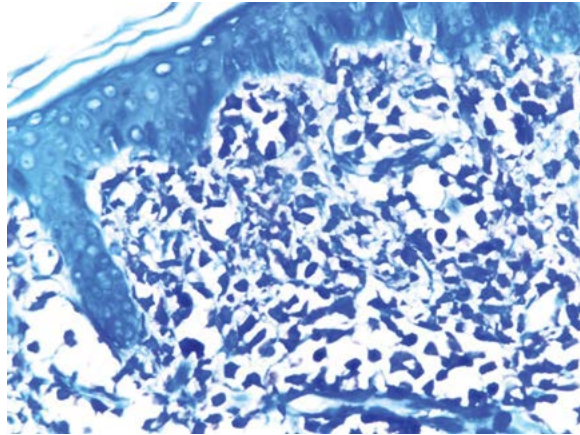
**Figure 1.** Brownish Papules and plaques on the back

We have performed a punch biopsy on one of the papular lesions on the back. Dense cell infiltration, with oval nuclei, eosinophilic or amphophilic cytoplasm was demonstrated in the superficial dermis with hematoxylin and eosin stain (Figure 2). Cells were also observed in perivascular and interstitial areas of superficial reticular dermis, scattered between collagen fibers. In some of the cells, nuclei were observed in reniform shape. Staining of cytoplasm by Toluidine blue (Figure 3), C-kit (CD117) (Figure 4) and CD68 (Figure 5) were demonstrated. There was also staining of several

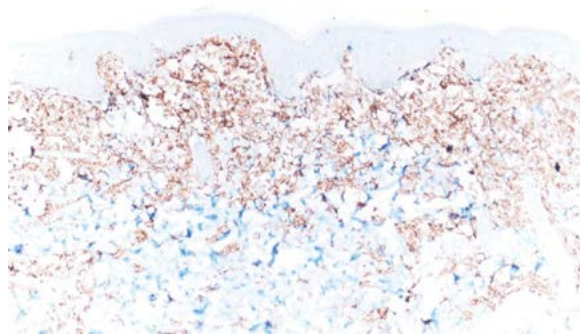


**Figure 2.** Dense cell infiltration of dermis hematoxylin and eosin section

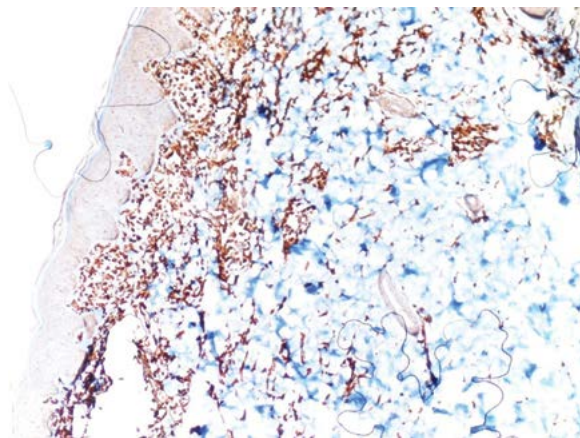
cells in the dermis by S100 (Figure 6) and CD1a (Figure 7), which are indicator of Langerhans cells.



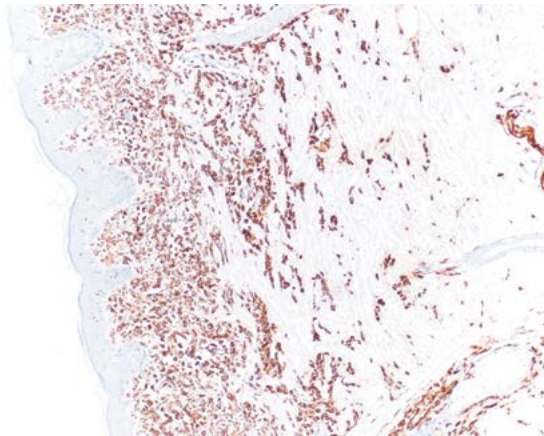
**Figure 3.** Mast cells with metachromatic granules in the dermis that were demonstrated with Toluidine blue stain



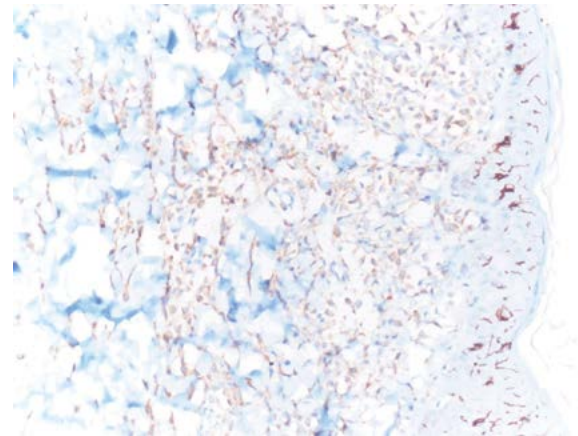
**Figure 4.** C-Kit-positive staining of mast cells



**Figure 5.** CD68 positive staining of mast cells



**Figure 6.** Langerhans cells stained strongly for S100



**Figure 7.** CD1a stained Langerhans cells

	Case 1	Case 2	Case 3	Case 4	Case 5
<b>Age</b>	2 years	2 months	13 years	27 years	9 months
<b>Gender</b>	Male	Male	Female	Male	Female
<b>Dermatologic examination</b>	Multiple red brown, maculo-papular lesions on the face, trunk, and extremities  Positive Darier's sign.	Red brown papules on the ankles, dorsum of the feet, and left axilla  Urticarial plaques involving the cheeks, chest, back, and extremities  Positive Darier's sign	Extensive skin lesions on the face, trunk, and extremities  Positive Darier's sign	Inguinal intertrigo-like lesions bilaterally  Positive Darier's sign	Red brown slightly raised papules and plaques on chest, abdomen, back, neck and left leg  Positive Darier's sign
<b>Histopathologic examination</b>	Langerhans cells intermingled with massive mast cells in the dermis.  Toluidine blue + CD1a +	Infiltrate of mononuclear cells, neutrophils, eosinophils, and mast cells involving the papillary dermis.  Toluidine blue + CD1a +	Infiltrate composed of histiocytes, mast cells, eosinophils, and lymphoid cells  Toluidine blue unexamined CD1a +	A mixed infiltration of mast cell and histiocytes in the dermis predominated by the latter.  Toluidine blue + CD1a -	Dense cell infiltration of mast and Langerhans cells  Toluidine blue + CD1a +
<b>Diagnosis</b>	Cutaneous mastocytosis with Langerhans cell infiltration	Urticating Hashimoto–Pritzker Langerhans Cell Histiocytosis	Urticating histiocytosis	Inguinal mastocytosis with histiocyte infiltration	Mastocytosis with prominent Langerhans cell infiltration

**Table 1.** Summary of cases

The patient has received topical 0.1% hydrocortisone-1-butyrate and oral ketotifen. After treatment, lesions became flatter and faded.

## Discussion

Mastocytosis is a rare disease that can present with diverse symptoms, according to the site of accumulation of mast cells (5). We should evaluate the patient for systemic involvement after diagnosis of mastocytosis in skin (5, 6). Cutaneous mastocytosis usually develops in childhood and has a favorable prognosis, with spontaneous remissions often seen in puberty (6-8, 10). The lesions are usually brownish maculopapular lesions and Darier's sign is positive. Anti-mast cell mediator drugs (eg. antihistamines), topical steroids and phototherapy can be chosen for treatment (5).

LCH is also characterized by a clonal proliferation of pathologic cells with the characteristics of Langerhans cells and can affect multiple organ systems (9, 12). Approximately half of the patients with LCH present cutaneous involvement (12, 13). Diverse cutaneous lesions may be presented such as hyperpigmented, hypopigmented, eroded, xanthoma-like patches and papules (13). For treatment, topical chemotherapeutic agents, topical corticosteroids and phototherapy may be used (9, 12).


Histopathological examination of mastocytosis stains, such as Giemsa, Toluidine Blue and anti-tryptase reveals focal accumulations of mast cells in dermis (7, 10). In our case, staining by Toluidine blue and CD1a is demonstrated. The new entity is described as mastocytosis with Langerhans cells infiltrates or LCH with mast cells infiltrates by different authors (1-4). Histopathologic examination of LCH reveals histiocytes which may have reniform nuclei (2). CD1 stain is gold standard for diagnosis of LCH (9).

The final diagnosis in our patient has been established by dermatologic and histopathologic evaluation. This paper presents an extremely rare case which shows both mast and langerhans cell proliferation. We prefer to describe this case as a mastocytosis case with prominent Langerhans cell infiltration.

*Financial disclosure: none declared.*

*Conflicts of interest: none declared.*

*Patient consent obtained.*

 This work is licensed under a Creative Commons Attribution 4.0 Unported License. The images or other third party material in this article are included in the article's Creative Commons license, unless indicated otherwise in the credit line; if the material is not included under the Creative Commons license, users will need to obtain permission from the license holder to reproduce the material. To view a copy of this license, visit <http://creativecommons.org/licenses/by-nc/4.0/>

## Bibliography

- Mitsuya J, Hara H, Fukuda N, et al. A Case of Cutaneous Mastocytosis in a Child with Prominent Langerhans Cell Infiltration. *Pediatr Dermatol* 2011;28:412-415.
- Butler DF, Ranatunge BD, Rapini RP. Urticating Hashimoto-Pritzker Langerhans Cell Histiocytosis. *Pediatr Dermatol* 2001;18:41-44.
- Foucar E, Piette WW, Tse DT, et al. Urticating histiocytosis: a mast cell-rich variant of histiocytosis X. *J Am Acad Dermatol* 1986;14:867-873.
- Enginger V, Bedane C, Pistorius MA, et al. Inguinal mastocytosis with histiocytic infiltrate. *Ann Dermatol Venereol* 1995;122:536-539.
- Valent P, Akin C, Escibano L, et al. Standards and standardization in mastocytosis: consensus statement on diagnostics treatment recommendations and response criteria. *Eur J Clin Invest* 2007;37:435-453.
- Wolff K, Komar M, Petzelbauer P. Clinical and histopathological aspects of cutaneous mastocytosis. *Leuk Res* 2001;25:519-528.
- Valent P, Horny H-P, Li CY, Longley JB, et al. Mastocytosis (mast cell disease). Tumours of Haematopoietic and Lymphoid Tissues. In: *World Health Organization (WHO) Classification of Tumours. Pathology & Genetics*. Jaffe ES, Harris NL, Stein H, Vardiman JW, editors. Lyon, France: IARC Press; 2001;1:291-302.
- Hartmann K, Henz BM. Cutaneous mastocytosis - clinical heterogeneity. *Int Arch Allergy Immunol* 2002;127:143-146.
- Abla O, Egeler RM, Weitzman S. Langerhans cell histiocytosis: current concepts and treatments. *Cancer Treat Rev* 2010;4:354-359.
- Valent P, Horny HP, Escibano L, et al. Diagnostic criteria and classification of mastocytosis: a consensus proposal. *Leuk Res* 2001;25:603-625.
- Favara BE, Jaffe R. The histopathology of Langerhans cell histiocytosis. *Br J Cancer Suppl* 1994;23:S17-S23.
- S. Munn, A.C. Chu. Langerhans cell histiocytosis of the skin. *Hematol Oncol Clin North Am* 1998;2:269-286.
- Simko SJ, Garmezay B, Abhyankar H, et al. Differentiating skin-limited and multisystem Langerhans cell histiocytosis. *J Pediatr* 2014;5:990-996.