



A rare case of cardiac anomaly: prenatally diagnosed ectopia cordis

Yalçın Çelik¹, Olgu Halloğlu², Nursel Basut³, Hasan Demetgül², A. Esin Kibar⁴

¹Department of Pediatrics, Division of Neonatology, Mersin University Faculty of Medicine, Mersin, Turkey

²Department of Pediatrics, Division of Pediatric Cardiology, Mersin University Faculty of Medicine, Mersin, Turkey

³Department of Pediatrics, Mersin University Faculty of Medicine, Mersin, Turkey

⁴Clinic of Pediatric Cardiology, Mersin women's and Children's Hospital, Mersin, Turkey

Abstract

Ectopia cordis is a rare congenital malformation in which the heart is located partially or totally outside the thoracic cavity. The estimated prevalence of ectopia cordis is 5.5-7.9 per million births and it comprises 0.1% of congenital heart diseases. Ectopia cordis is associated with other congenital heart diseases and various tissue and organ disorders. Common cardiac anomalies associated with ectopia cordis include ventricular septal defect, atrial septal defect, pulmonary stenosis, right ventricular diverticulum, double right ventricular outflow tract and tetralogy of Fallot. Extracardiac anomalies associated with ectopia cordis reported in the literature include omphalocele, gastrochisis, cleft lip and palate, scoliosis and central nervous system malformations. Here we report a newborn with ectopia cordis who was diagnosed prenatally. (Turk Pediatri Ars 2015; 50: 129-31)

Keywords: Pentalogy of Cantrell, Ectopia cordis, midline developmental anomalies

Introduction

Ectopia cordis is a rare congenital malformation in which the heart is located partially or totally outside the thoracic cavity (1-5). It occurs with a prevalence of 5.5-7.9 in one million live births (1.4-6). Its frequency among all congenital heart diseases is 0.1% (1.5). Ectopia cordis may occur alone or in accompaniment with other congenital heart diseases, central nervous system disorders and disorders including omphalocele, gastrochisis and cleft lip-palate (5). Here, a case of ectopia cordis diagnosed in the prenatal period is presented because it is observed rarely.

Case

The heart of a female baby born with a birth weight of 2 100 g at the 32nd gestational week by cesarean section from the first pregnancy of a 20-year mother was completely outside the thoracic cavity (Figure 1). The baby whose respiratory effort was absent after delivery and

who had central cyanosis was intubated and internalized in the neonatal intensive care unit. In the history, it was learned that fetal echocardiography performed in the 24th gestational week in our hospital revealed that the baby's heart was outside the thoracic cavity, a single atrium, hypoplastic right ventricle, ventricular septal defect and pulmonary atresia were present (Figure 2, 3). The mother had no history of morbidity before pregnancy or during pregnancy, did not use medication and was not exposed to radiation. In the familial history, it was learned that there was no familial history of congenital disorder or important morbidity and there was no consanguineous marriage between the mother and father. On physical examination, the baby's face, neck and trunk were edematous, the heart was completely outside of the thoracic cavity, there was no pericardium on the heart, the cardiac beats could be observed and the heart rate was 80/min. There was defect in the

This case report was presented at the 21th National Neonatology Congress, 14-17 April 2013, Antalya.

Address for Correspondence: Yalçın Çelik, Mersin Üniversitesi Tıp Fakültesi, Çocuk Sağlığı ve Hastalıkları Anabilim Dalı, Yenidoğan Bilim Dalı, Mersin, Türkiye. E-mail: drycelik@yahoo.com

Received: 28.02.2013 **Accepted:** 13.08.2013

©Copyright 2015 by Turkish Pediatric Association - Available online at www.turkpediatriarsivi.com

DOI: 10.5152/tpa.2015.927

abdominal wall above the umbilicus, abdominal distention was present, but there was no hepatomegaly or splenomegaly. The external genitalia were female in appearance. The patient who was intubated after delivery and in whom mechanical ventilation was initiated was lost in a short time in the follow-up. Written informed consent was obtained from the family of the patient.

Discussion

Ectopia cordis has been known for 5 000 years, but its etiology and pathogenesis has not been elucidated yet (2, 6-8). In the pathogenesis, lack of completion of the normal developmental process of the sternum and thoracic wall is blamed (5, 6). Although ectopia cordis mostly occurs sporadically, familial cases have been reported rarely (7). Generally, there is no risk factor in the patients. However, it has been reported that ectopia cordis may be associated with viral infections, exposure to teratogens and chromosomal disorders including Trisomy 18 and Turner syndrome (2, 6-8). There was no known risk factor in the personal history and familial history of our patient. On physical examination, no findings suggesting trisomy, Turner syndrome or other syndromes were present, but chromosomal analysis could not be performed.

Complete ectopia cordis is defined as the heart being located outside the thoracic cavity without an overlying pericardial sac and partial ectopia cordis is defined as the heart being located outside the thoracic cavity covered with pericardium and skin (7). Our patient had complete ectopia cordis. Ectopia cordis is divided into five groups depending on the localization of the heart as cervical, cervicothoracic, thoracic, thoracoabdominal and abdominal (2.6-7.9). Thoracoabdominal ectopia cordis may be a part of middle line defects defined as Cantrell’s pentology (4, 10). In Cantrell’s pentology, other congenital heart disorders are present in association with abdominal wall, sternum, diaphragm and pericardium disorders (1, 9). While cases with all of these five findings are defined as definite Cantrell’s pentology, cases with four of these five findings are defined as possible Cantrell’s pentology (1, 10). In our patient, the heart was localized in the thoracoabdominal region and

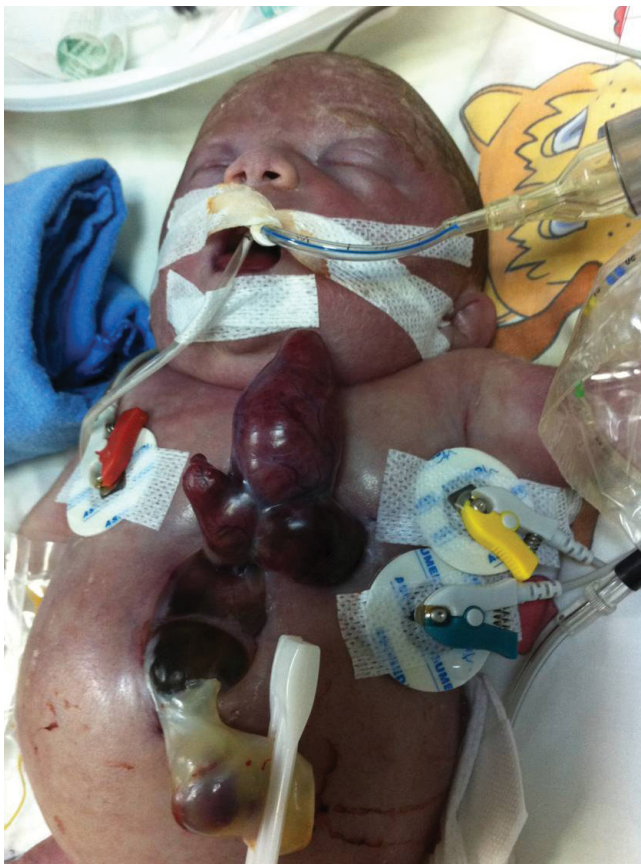

Figure 1. The heart of the patient outside the thoracic cavity and developmental disorder in the upper abdominal wall

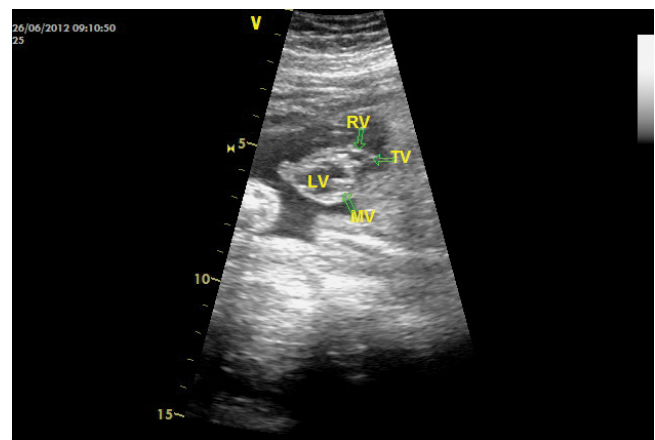


Figure 2. Fetal echocardiography reveals that the heart of the fetus is outside the thoracic cavity and inside the amniotic fluid

RV: right ventricle; LV: left ventricle; MV: mitral valve; TV: tricuspid valve

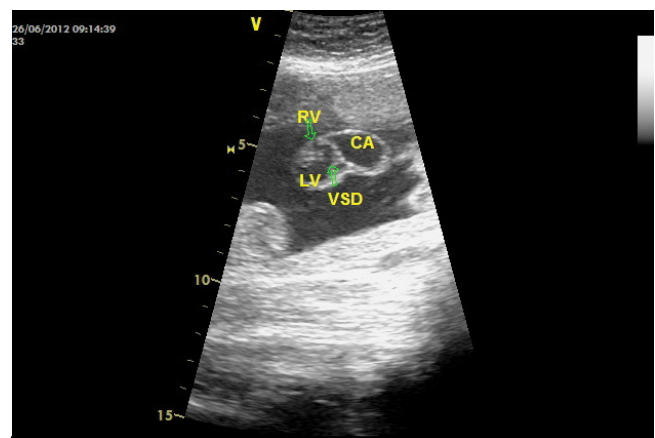


Figure 3. Fetal echocardiography reveals that the heart of the fetus is outside the thoracic cavity and a large single atrium and ventricular septal defect are present

RV: right ventricle; LV: left ventricle; VSD: ventricular septal defect; CA: single atrium

diaphragm disorder which is one of the five findings of Cantrell's pentology was absent.

Ectopia cordis is frequently accompanied by congenital heart disorders including ventricular septal defect, atrial septal defect, pulmonary stenosis, fallot tetralogy, right ventricular diverticle, double outlet right ventricle and more rarely with single ventricle, transposition of the great arteries and atrioventricular septal defect (1, 7, 9, 11). In addition, extracardiac disorders including omphalocele, gastrochisis, scoliosis, cleft lip-palate and central nervous system disorders may also be observed in association with ectopia cordis (4, 9). In our patient, there was no disorder related with the other systems and organs except for developmental disorder of the upper abdominal wall. The chance of survival in patients with ectopia cordis depends on the accompanying congenital disorders and most of the patients with severe congenital heart disorders are lost in the early period (1, 11). Ventricular septal defect, pulmonary atresia, single atrium and hypoplastic right ventricle were found in our patient and she was lost in a short time after delivery.

Ectopia cordis and accompanying congenital heart disorders can be detected in the prenatal period in the 10-12th weeks by vaginal fetal echocardiography and in the 20-22nd weeks by abdominal fetal echocardiography (2, 11, 12). Our patient presented to our hospital in the 24th gestational week and the diagnosis was made by fetal echocardiography performed by abdominal ultrasonography.

Conclusively, ectopia cordis is a rare congenital disorder which may be accompanied by other tissue and organ disorders. Termination of pregnancy may be recommended in cases with severe congenital heart disorders where the diagnosis is made in the early prenatal period.

Informed Consent: Written informed consent was obtained from the parent of the patient.

Peer-review: Externally peer-reviewed.

Author Contributions: Concept - Y.Ç., O.H.; Design - Y.Ç., O.H.; Supervision - Y.Ç., O.H., N.B., H.D., A.E.; Funding - Y.Ç., O.H., N.B., H.D., A.E.; Materials - Y.Ç., O.H., N.B., H.D., A.E.K.; Data Collection and/or Processing - Y.Ç., O.H., N.B., H.D., A.E.; Analysis and/or Interpretation - Y.Ç., O.H.; Literature Review - Y.Ç., O.H.; Writer - Y.Ç., O.H.; Critical Review - Y.Ç., O.H., N.B., H.D., A.E.

Conflict of Interest: No conflict of interest was declared by the authors.

Financial Disclosure: The authors declared that this study has received no financial support.

References

1. Tan LO, Lim SY, Sharif F. A 'One in a million' case of pulsating thoracoabdominal mass. *BMJ Case Rep* 2012. [CrossRef]
2. Shad J, Budhwani K, Biswas R. Thoracic ectopia cordis. *BMJ Case Rep* 2012. [CrossRef]
3. Mohan R, Peralta M, Perez R, Rosenkranz ER, Panthaki ZJ. Chest wall reconstruction in a pediatric patient with ectopia cordis. *Ann Plast Surg* 2010; 65: 211-3. [CrossRef]
4. İrdem A, Şafak T, Başpınar O et al. Torakoabdominal tip ektopia kordis: bir olgu sunumu. *Gaziantep Tıp Derg* 2012; 18: 115-7.
5. Sadlecki P, Krekora M, Krasomski G, et al. Prenatally evolving ectopia cordis with successful surgical treatment. *Fetal Diagn Ther* 2011; 30: 70-2. [CrossRef]
6. Keçeligil HT, Demirağ MK, Yücel SM, Yüksel A. Nadir rastlanan doğumsal kalp anomalisi: ektopia kordis. *Anadolu Kardiyol Derg* 2009; 9: 144-6.
7. Engum SA. Embryology, sternal clefts, ectopia cordis, and Cantrell's pentology. *Semin Pediatr Surg* 2008; 17: 154-60. [CrossRef]
8. Shaw SW, Cheng PJ, Chueh HY, Chang SD, Soong YK. Ectopia cordis in a fetus with trisomy 18. *J Clin Ultrasound* 2006; 34: 95-8. [CrossRef]
9. Alphonso N, Venugopal PS, Deshpande R, Anderson D. Complete thoracic ectopia cordis. *Eur J Cardiothorac Surg* 2003; 23: 426-8. [CrossRef]
10. Kılıç E, Alanay Y, Korkmaz A et al. Tam ektopia kordisli bir Cantrell pentolojisi vakası. *Çocuk Sağlığı Hast Derg* 2011; 54: 83-6.
11. Cabrera A, Rodrigo D, Luis MT, et al. Ectopia cordis and cardiac anomalies. *Rev Esp Cardiol* 2002; 55: 1209-12. [CrossRef]
12. Morales JM, Patel SG, Duff JA, Villareal LR, Simpson JW. Ectopia cordis and other midline defects. *Ann Thorac Surg* 2000; 70: 111-4. [CrossRef]